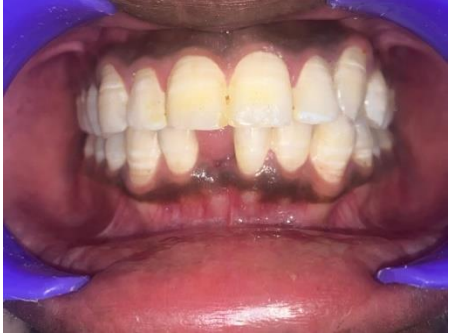
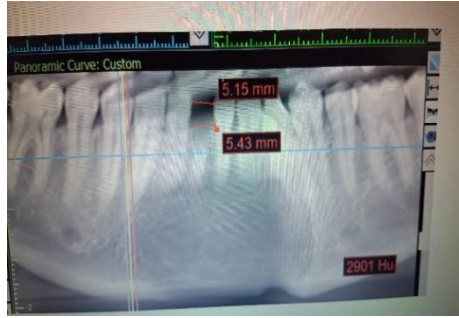
Patient name : Neela Reddy

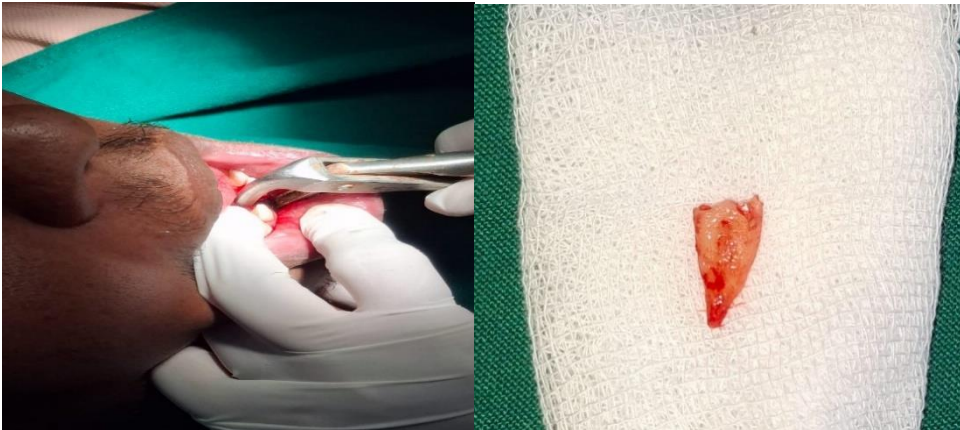
Treatment: Immediate implant placement



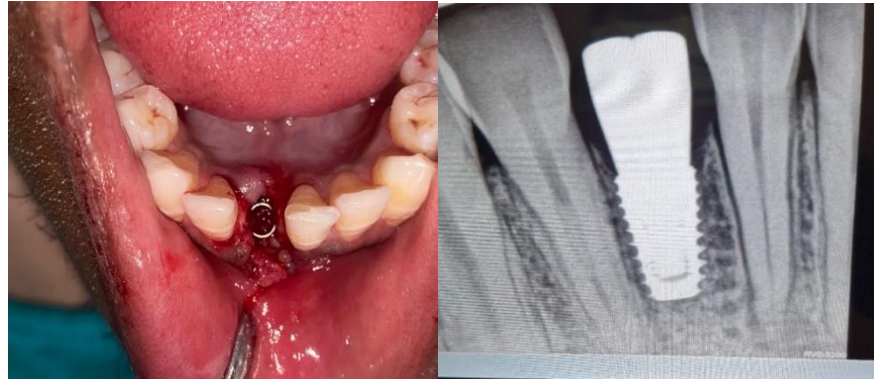
Pre-op intraoral view



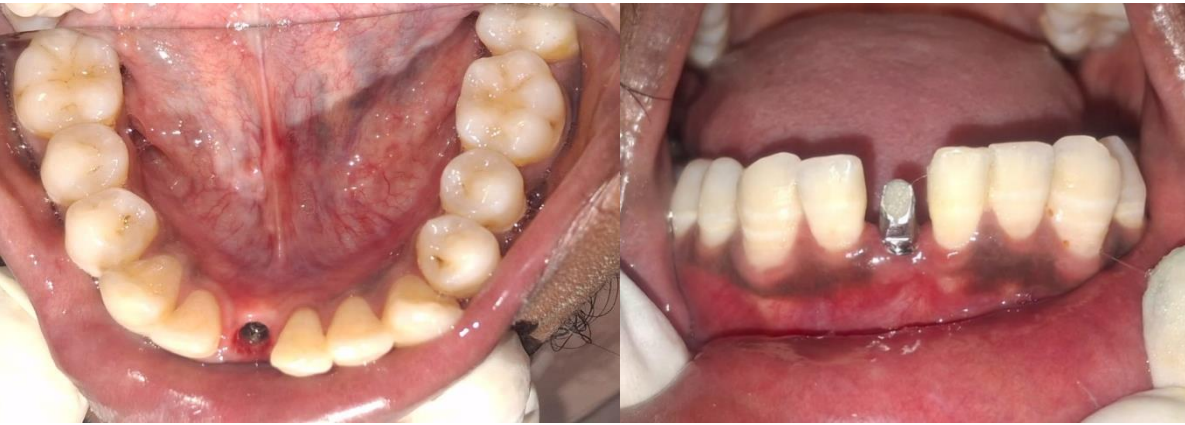Root stump seen in CBCT and  
implant planning was done  
accordingly for the site #41



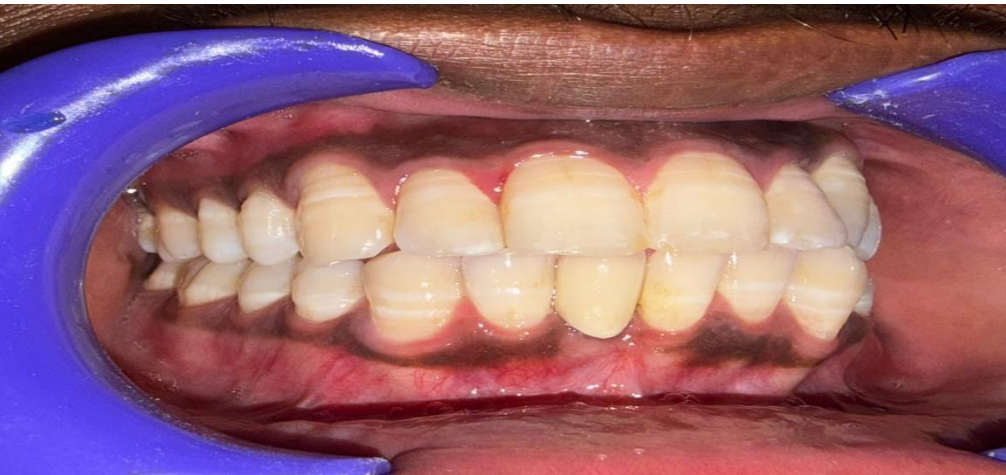Extraction of the retained root stump w.r.t #41



Immediate implant placed along with healing abutment placement



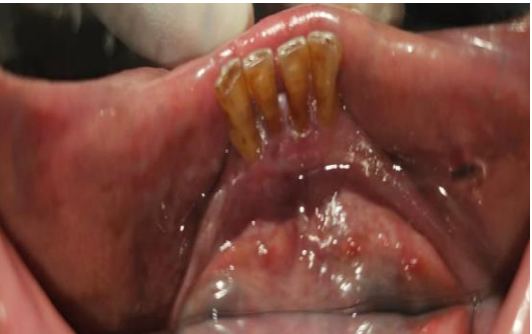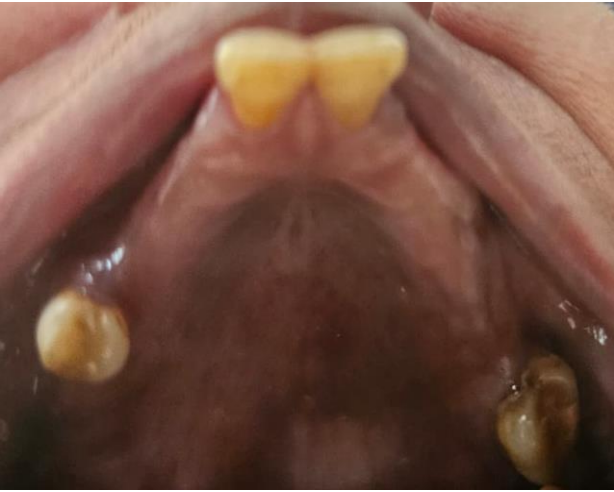Gingival contour after 3 months of healing and dual abutment placement



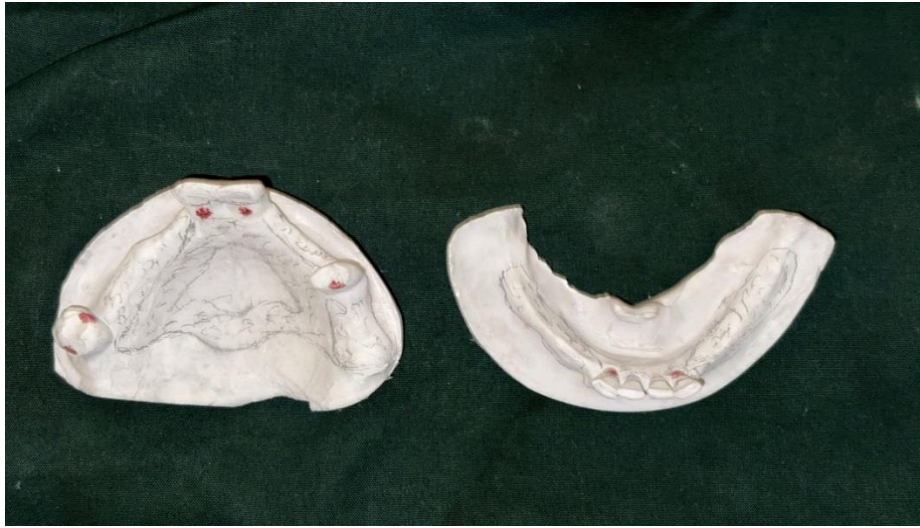Final cement retained PFM prosthesis placed

**Patient Name:** Suvarna

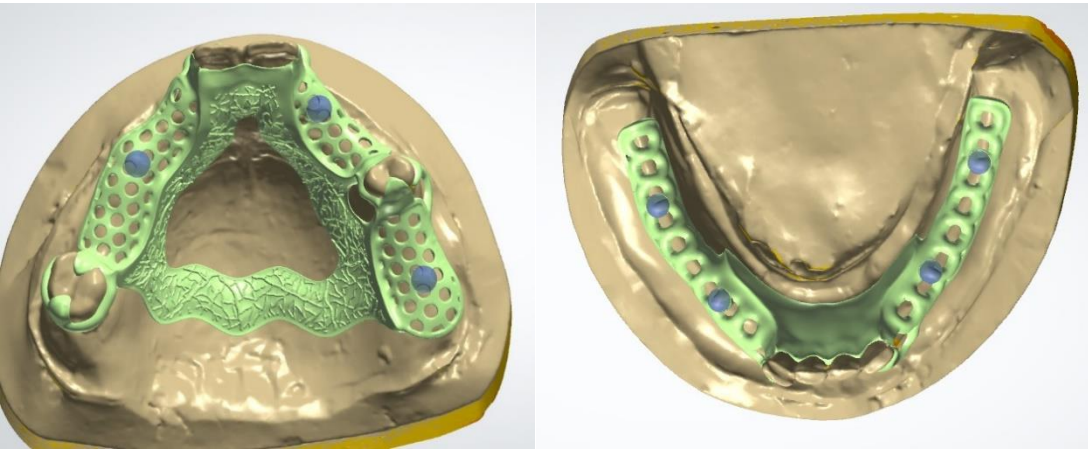
**Treatment :** Cast Partial Denture



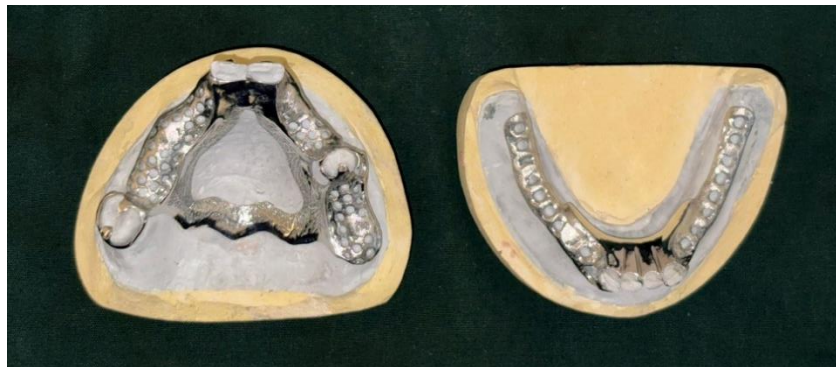Intraoral photographs with multiple missing teeth



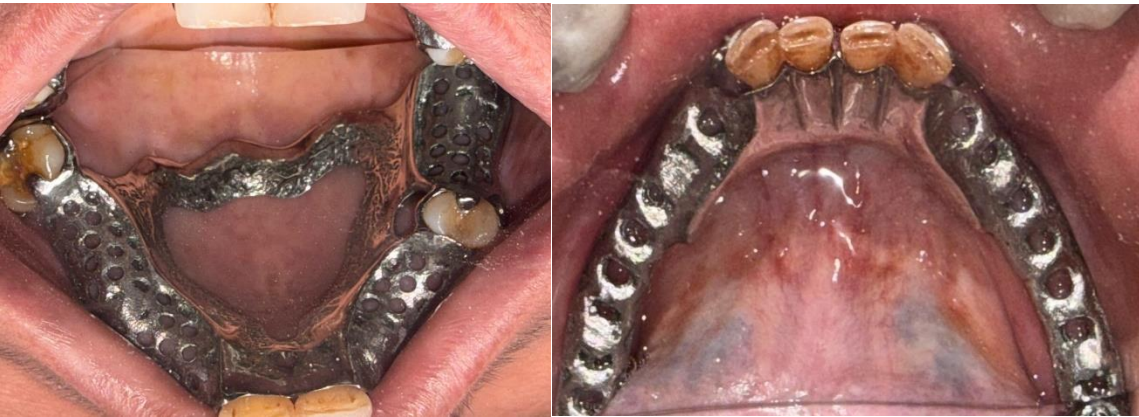Surveying and designing of the  
cpd done on diagnostic cast



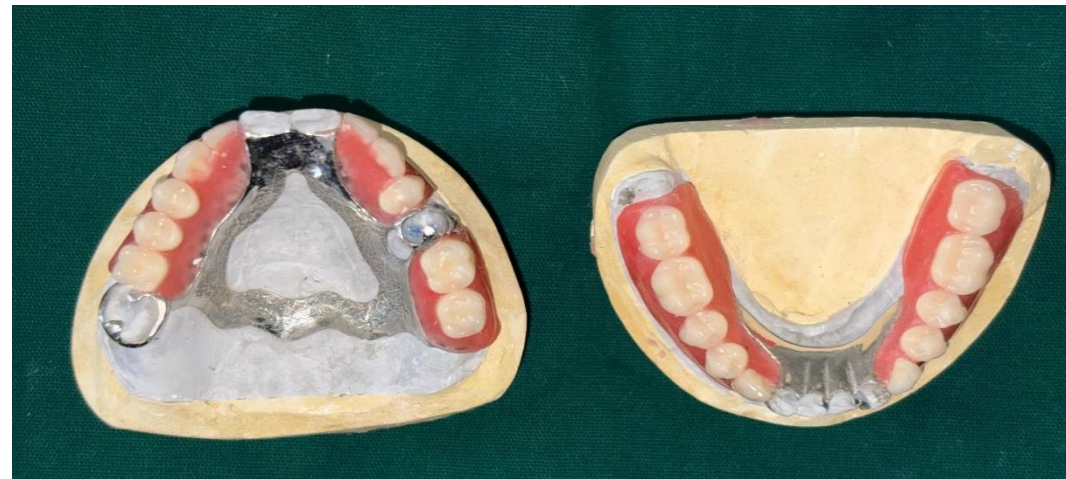Designing of the cpd framework done in CAD software



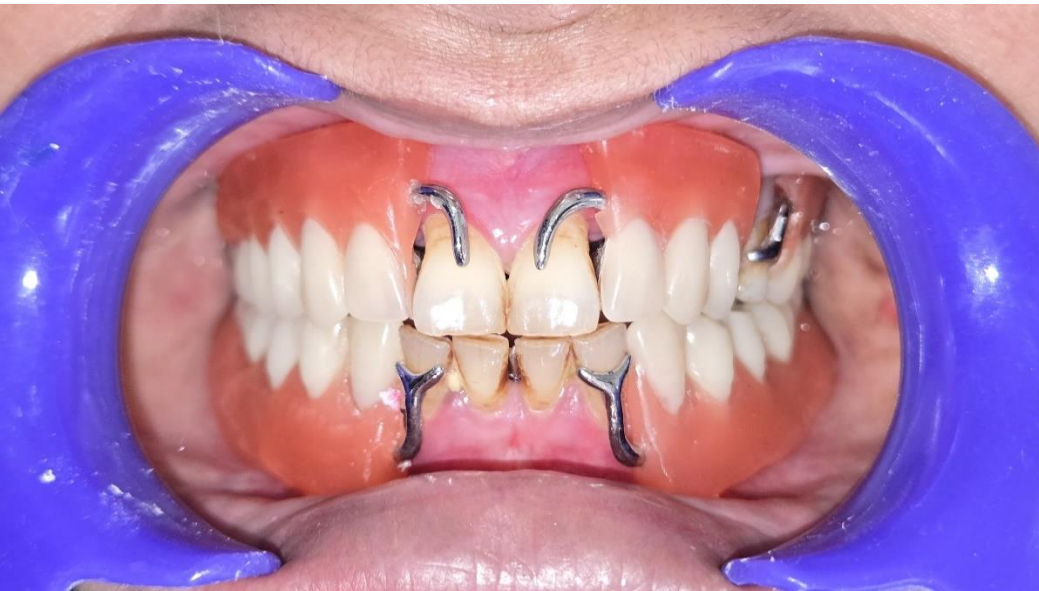Metal framework fabricated



Metal frameworks tried in patients mouth for both upper and lower arches



Teeth arrangement done for try-in



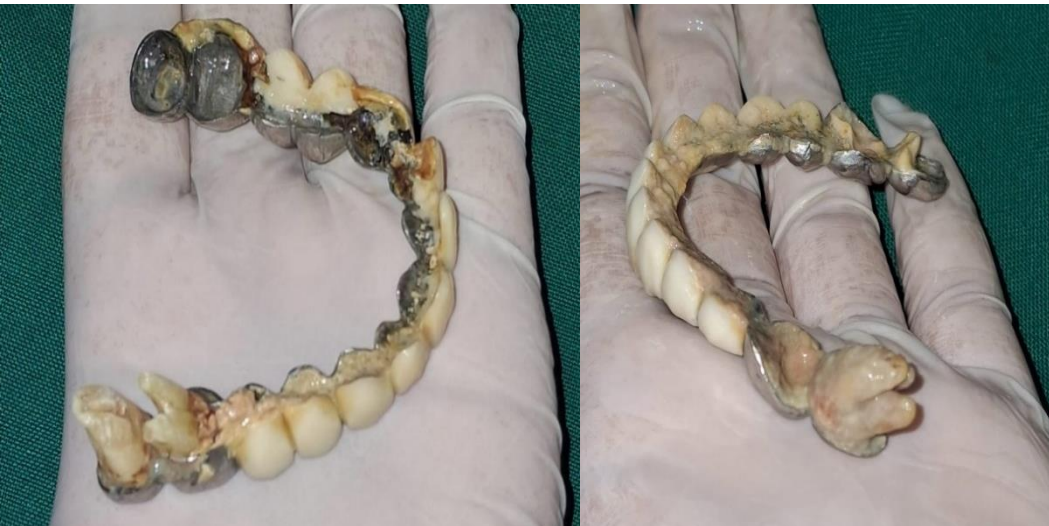CPD try-in done in patients mouth for maxilla and mandible

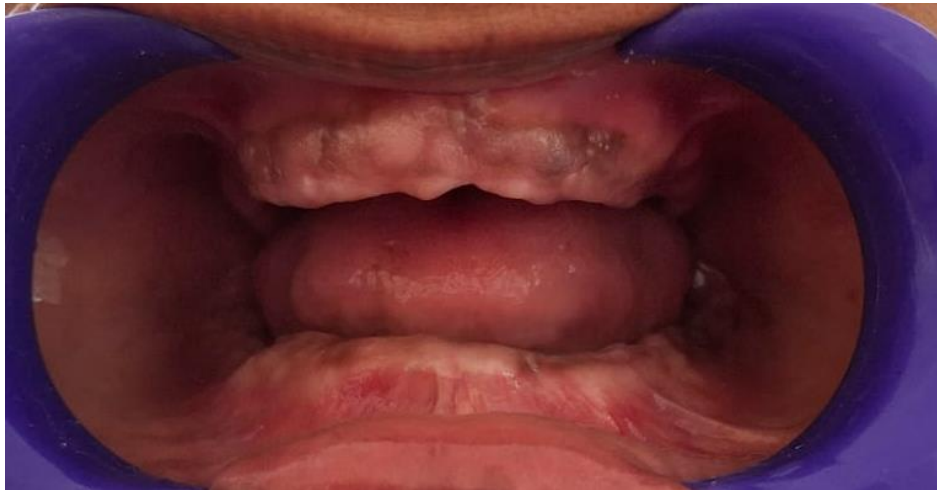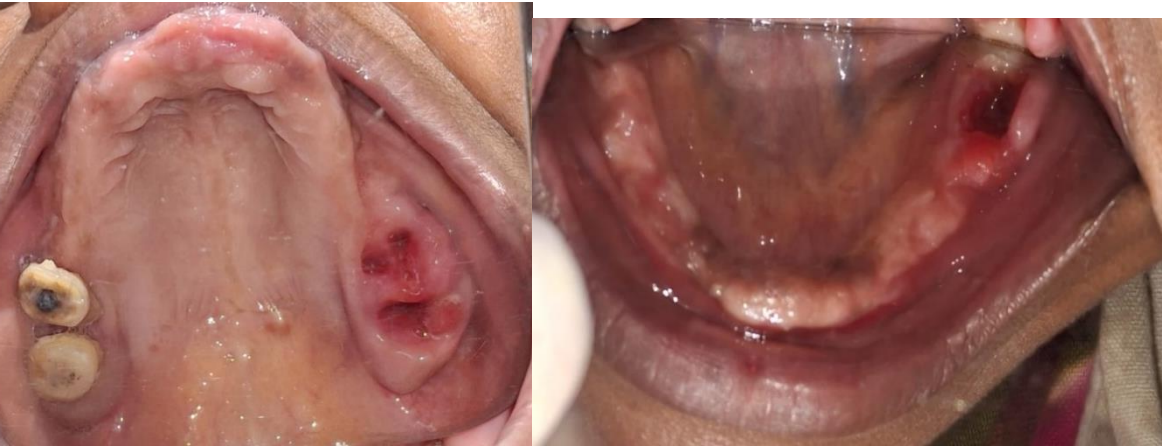**Patient Name:** Ramanjinamma

**Treatment :** Guided Full mouth implant rehabilitation

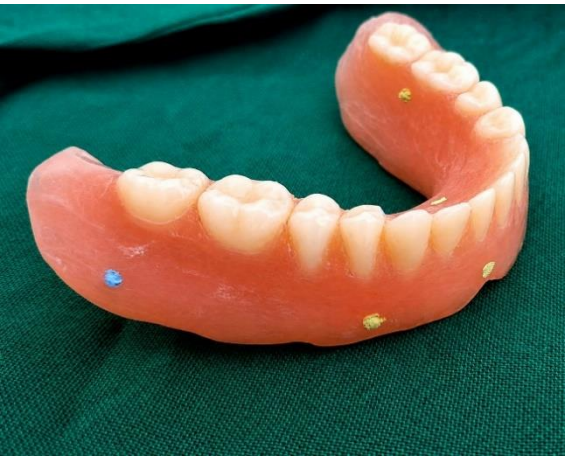
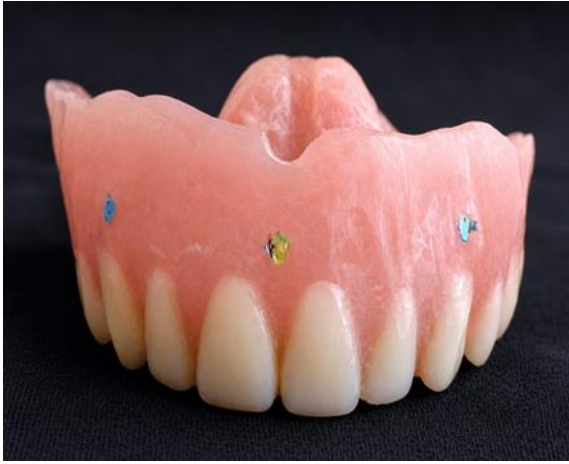
Pre-operative photographs of the patient with faulty prosthesis, where the patient wore the prosthesis along with avulsed teeth. Full mouth extraction was prescribed.

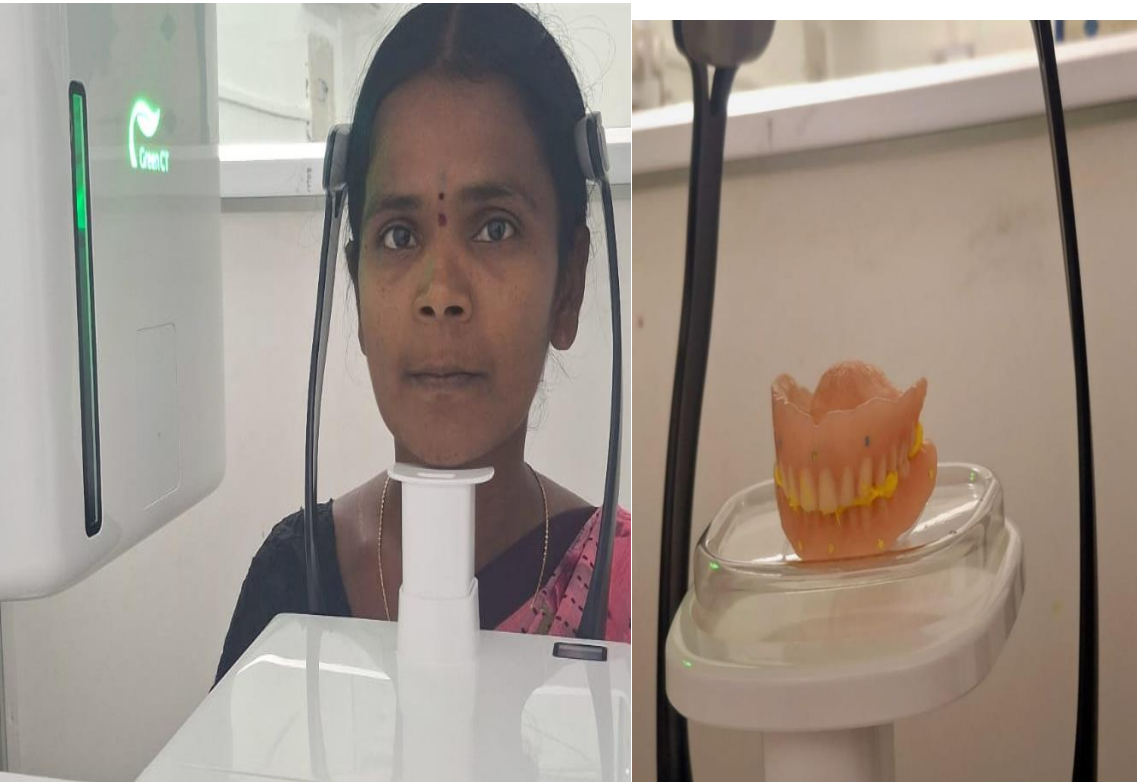



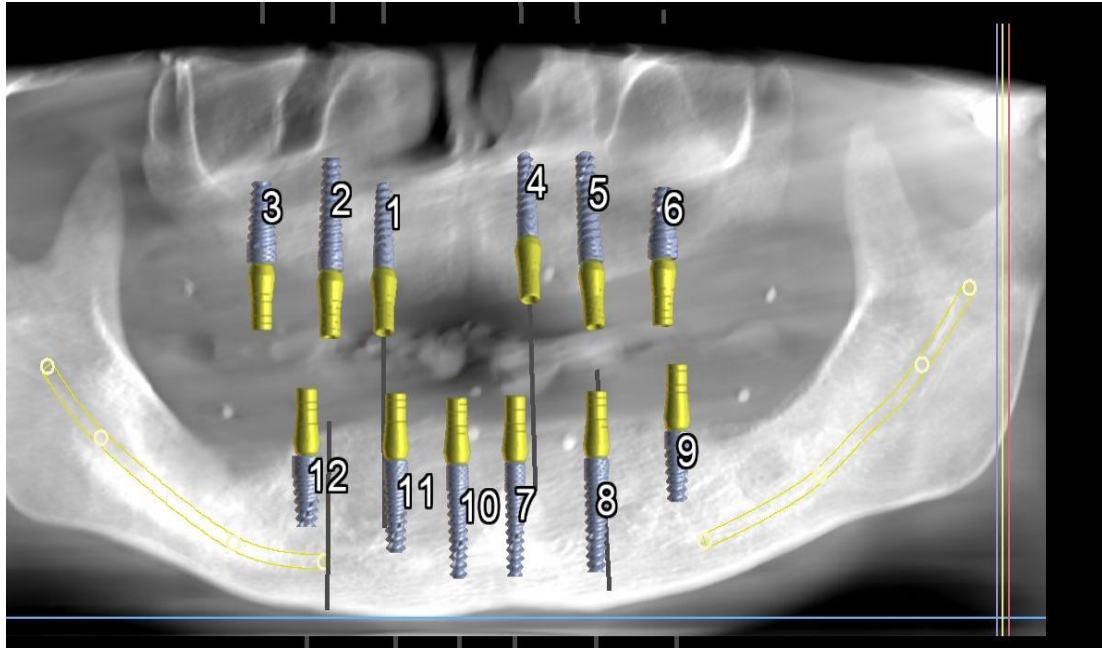
healing of the ridge seen after 1 month



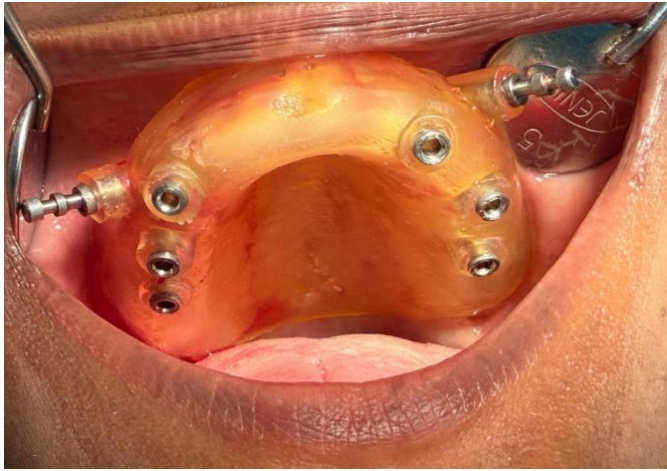
Conventional complete denture was fabricated and opaque reference marks were placed on the denture for dual scan CBCT technique.



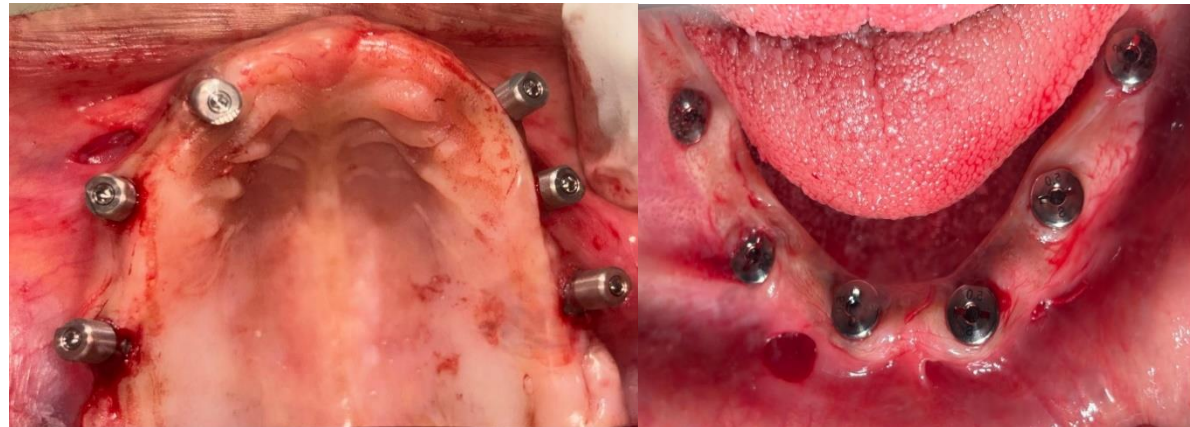
Dual scan CBCT was done 1) cbct scan of the patient with the denture in mouth 2) cbct of the the denture alone.



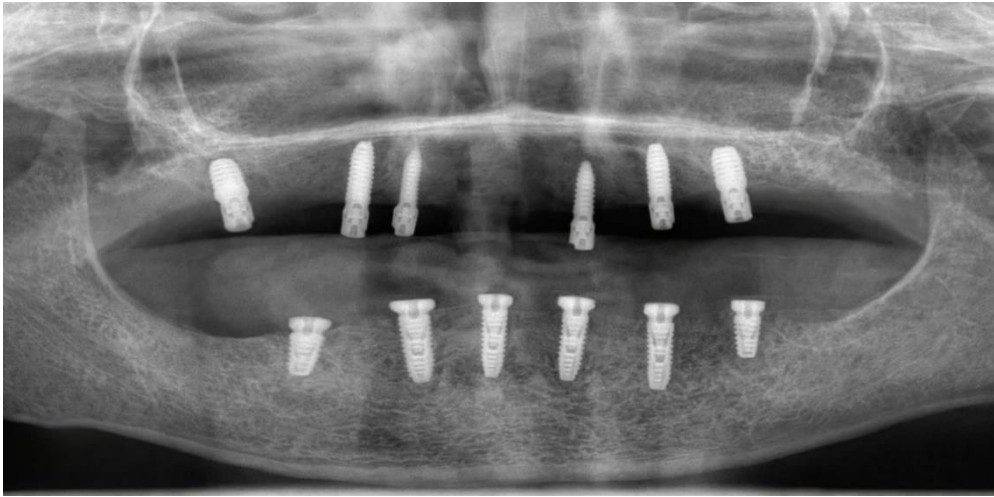
All on 6 implant planning was done for surgical guide fabrication



Surgical guide placed in patients mouth and stabilized with anchor pins

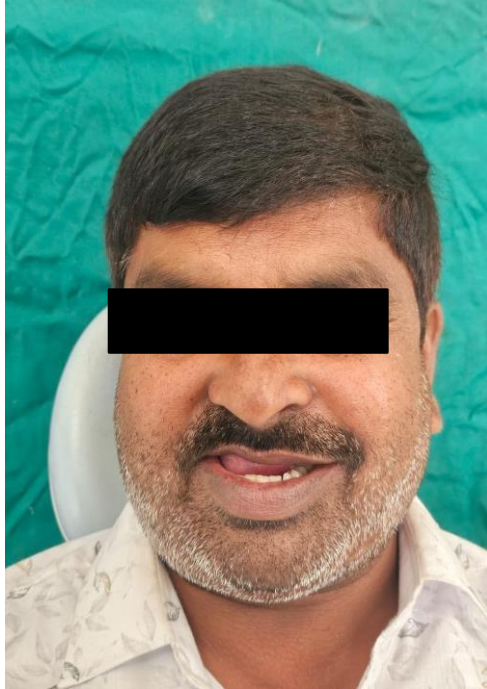

All on six implants placed along with scan comfort cap for maxilla and healing abutments placed for mandible

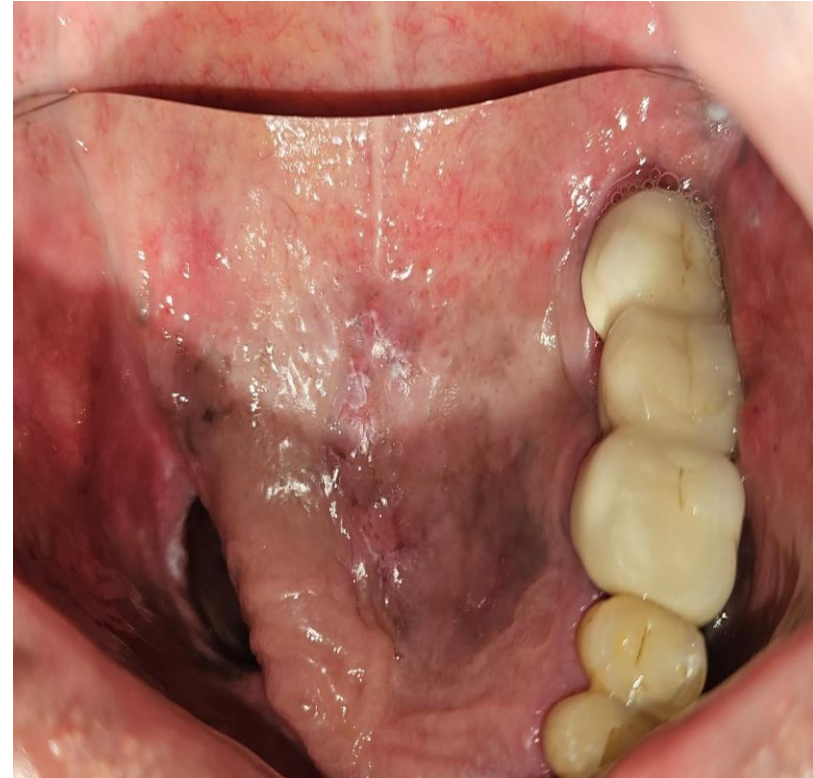

Post-operative radiograph after implant placement

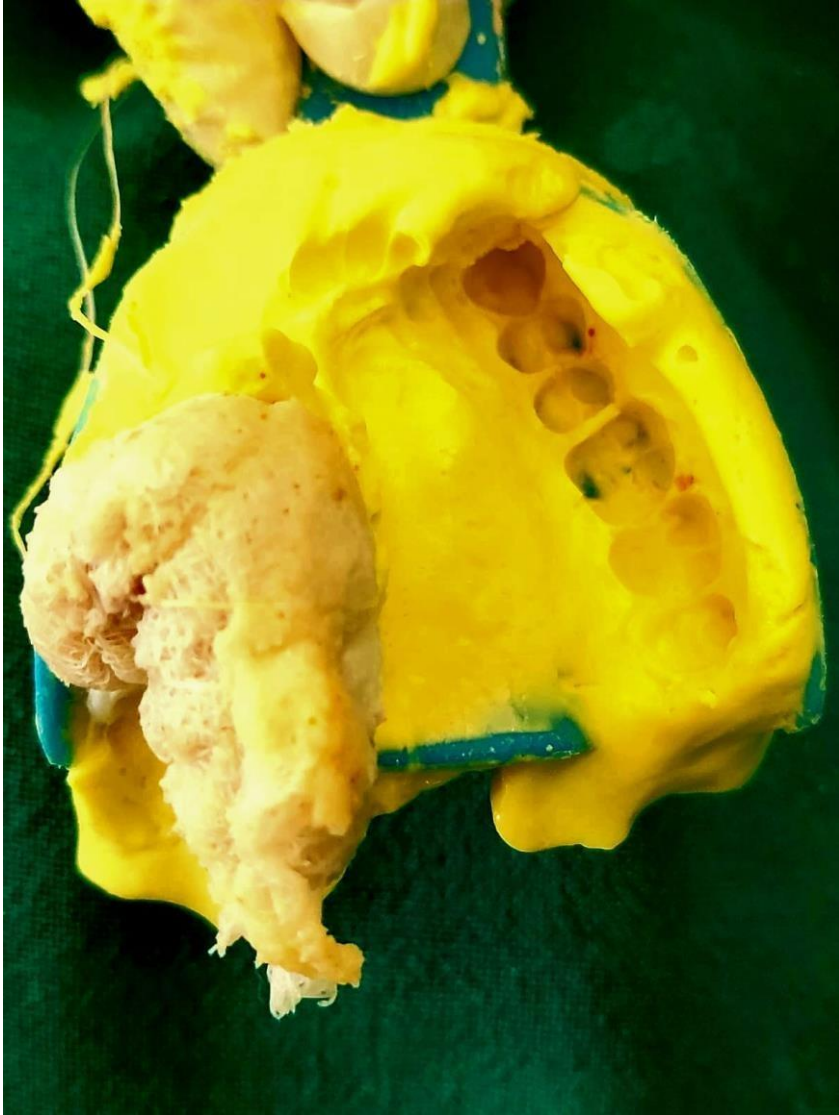**FABRICATION OF DEFINITIVE HOLLOW  
BULB OBTURATOR FOR A PATIENT WITH A  
MAXILLARY DEFECT-A CASE REPORT**



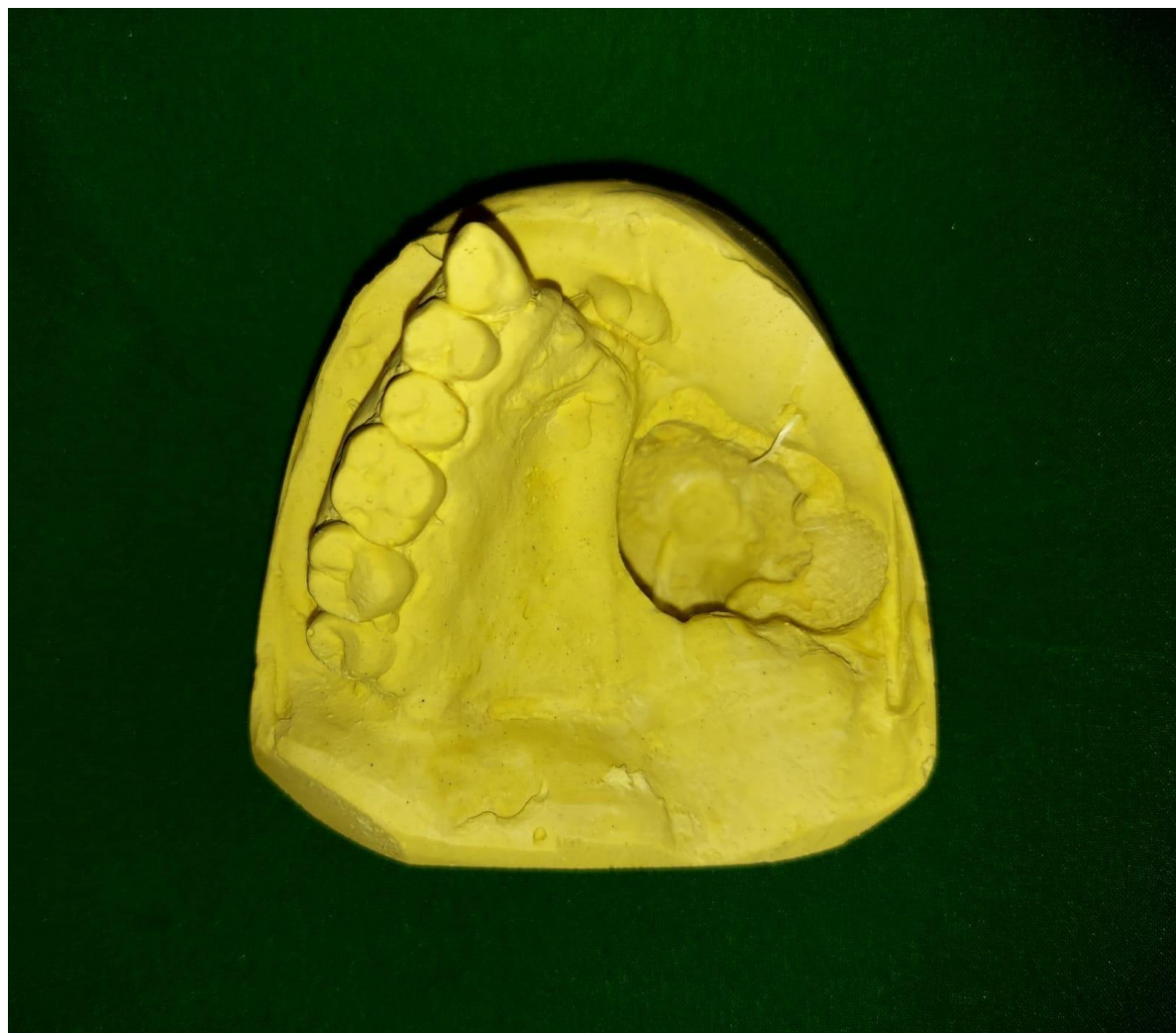
**PREOPERATIVE-  
EXTRAORAL  
PHOTOGRAPH**



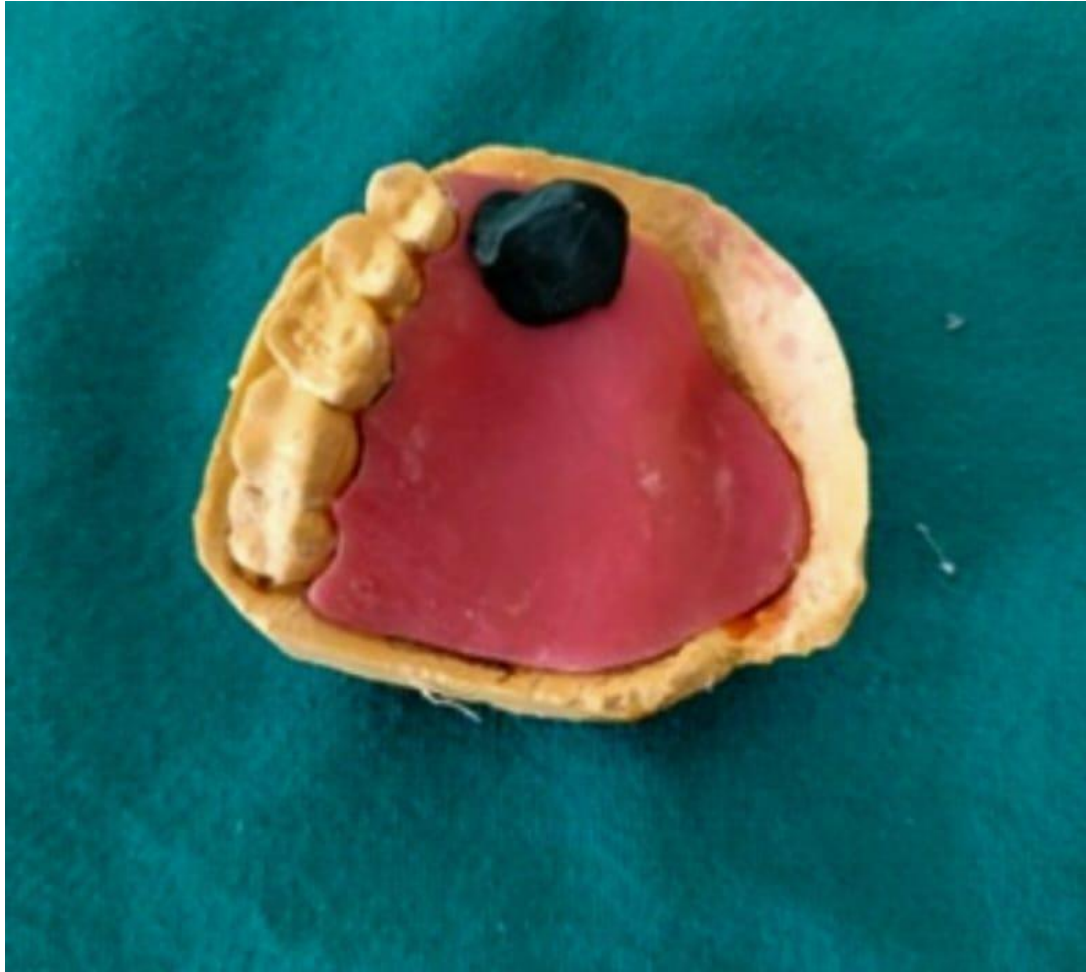**PREOPERATIVE- INTRAORAL  
PHOTOGRAPH**



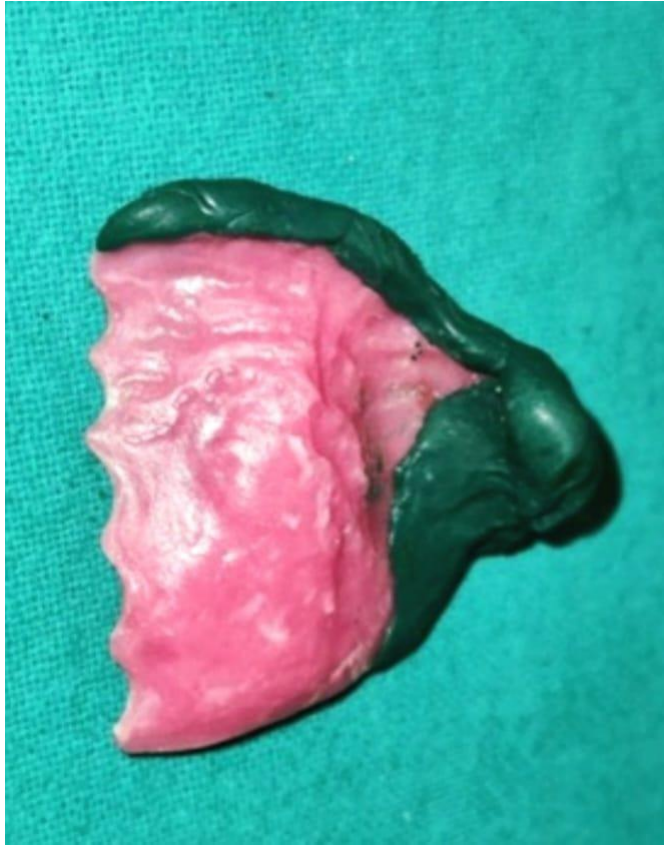**PRIMARY IMPRESSION-  
ALGINATE**



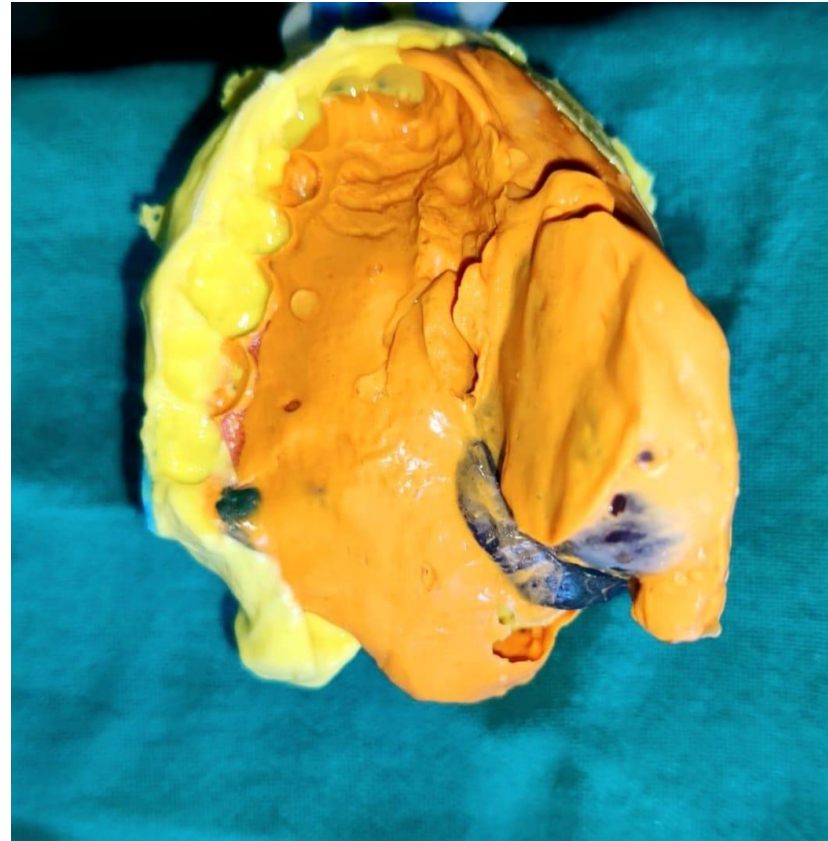
**PRIMARY CAST**



**SPECIAL TRAY**



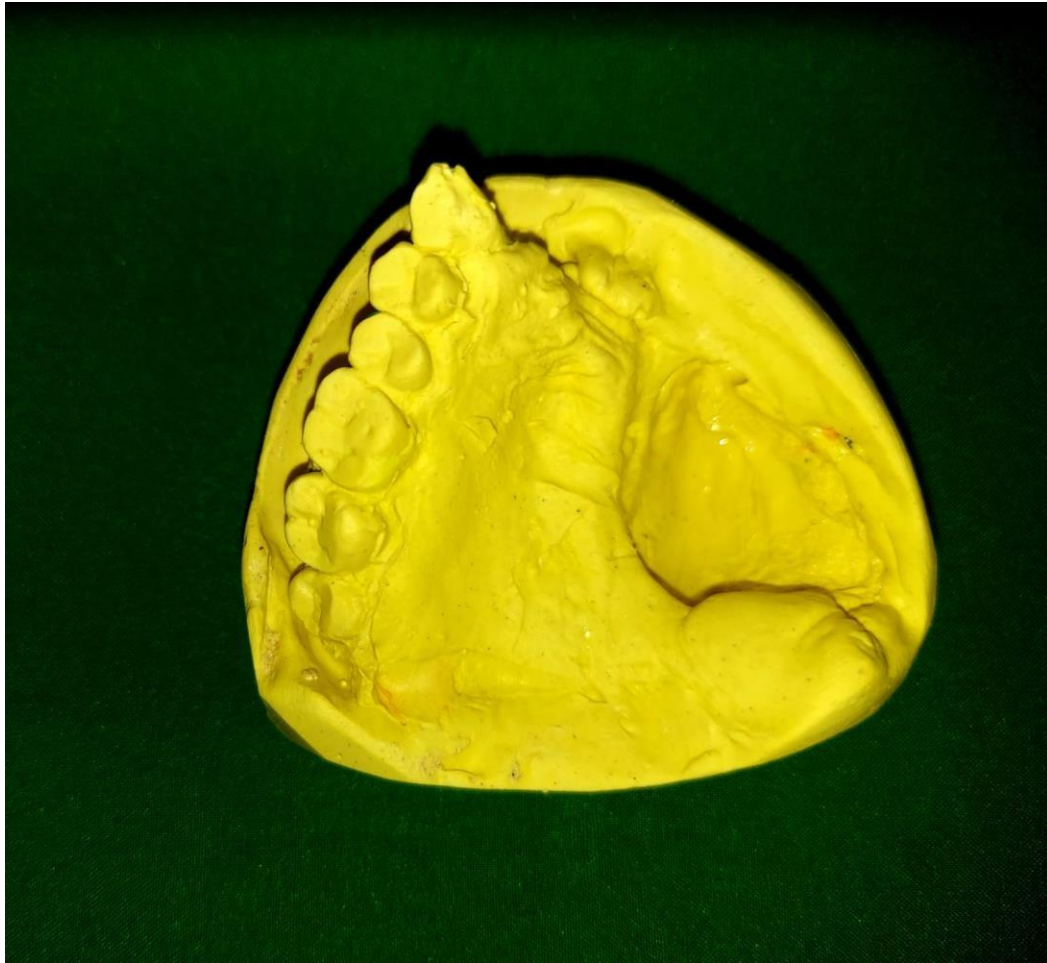
**BORDER MOLDING**



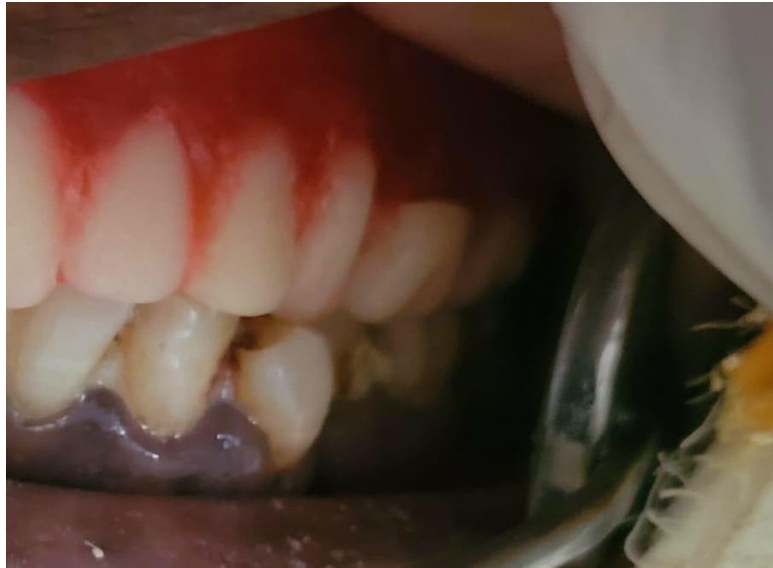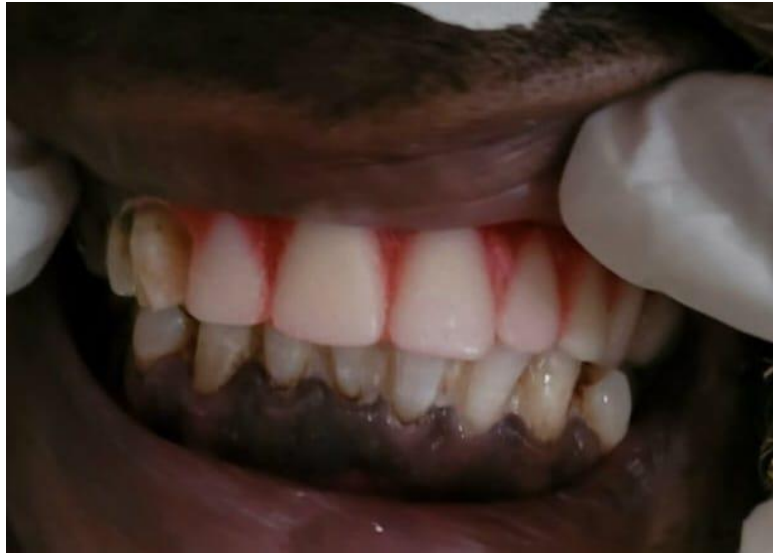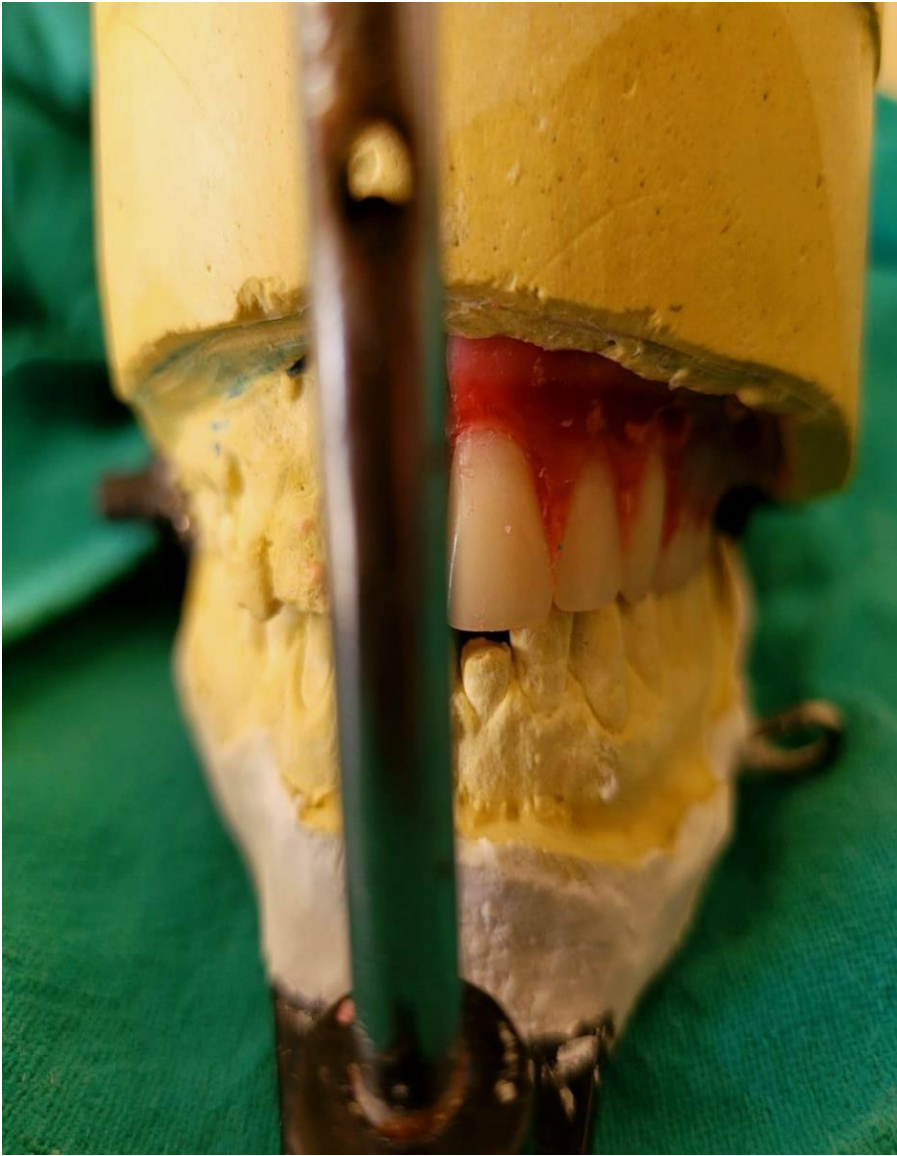
**SECONDARY IMPRESSION WAS  
TAKEN WITH LIGHT BODY  
FOLLOWED BY PICKUP  
IMPRESSION WITH ALGINATE**



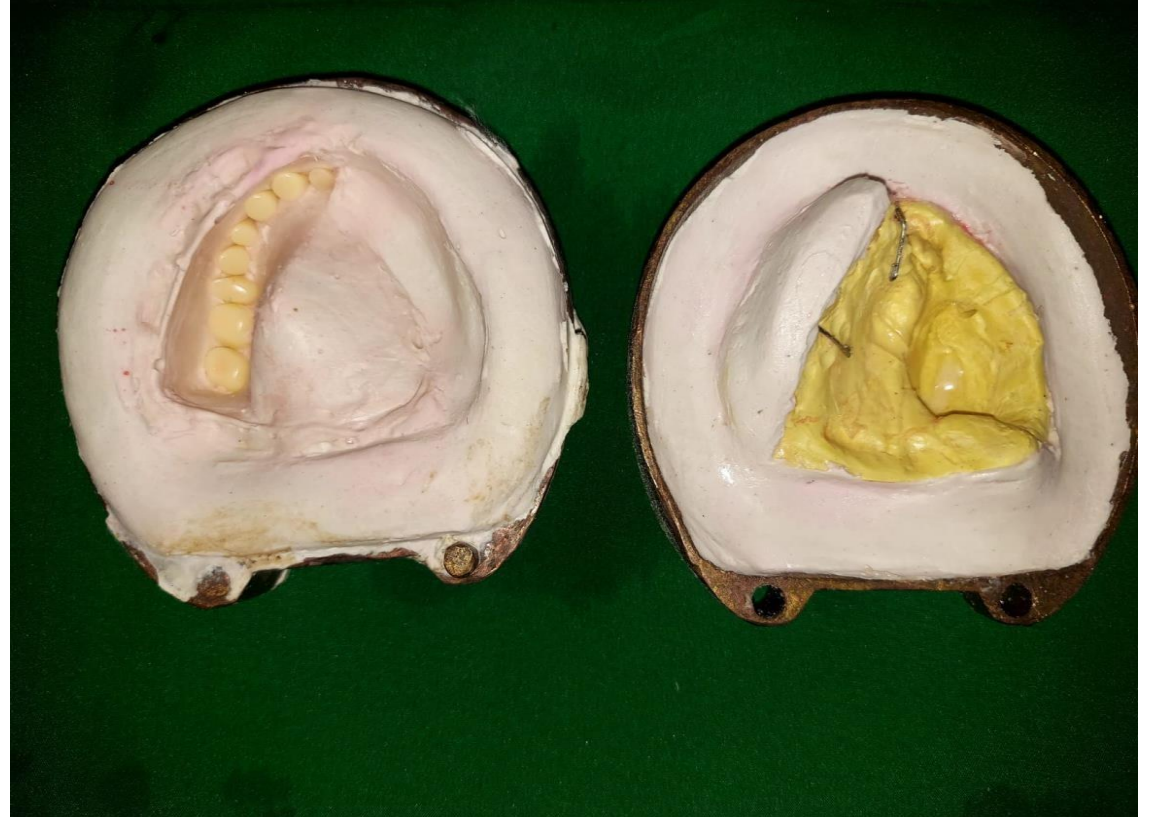**BEADING AND BOXING**



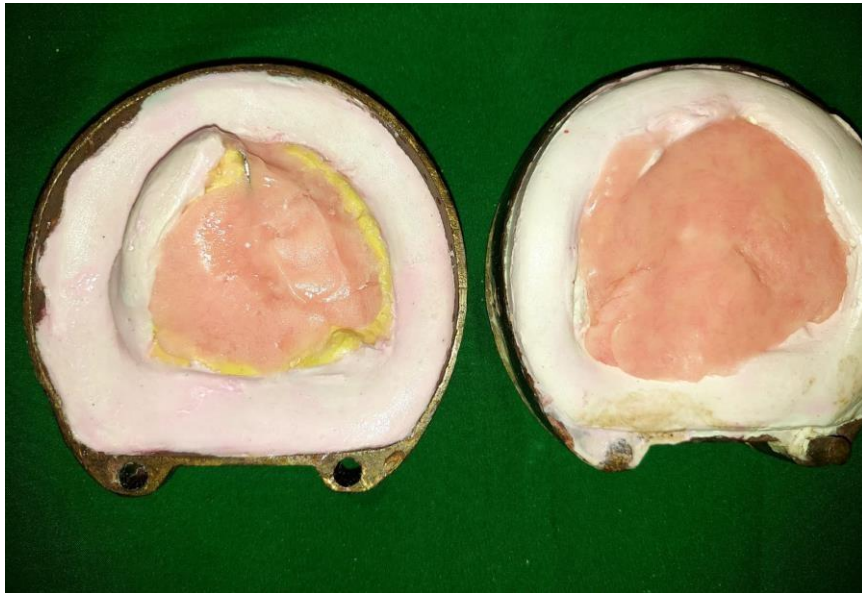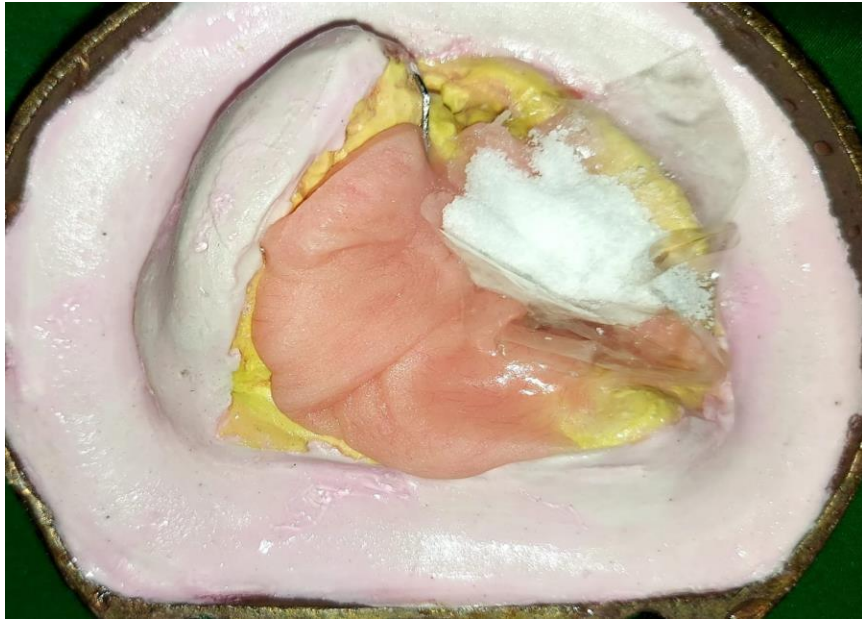**MASTER CAST**



TRY-IN



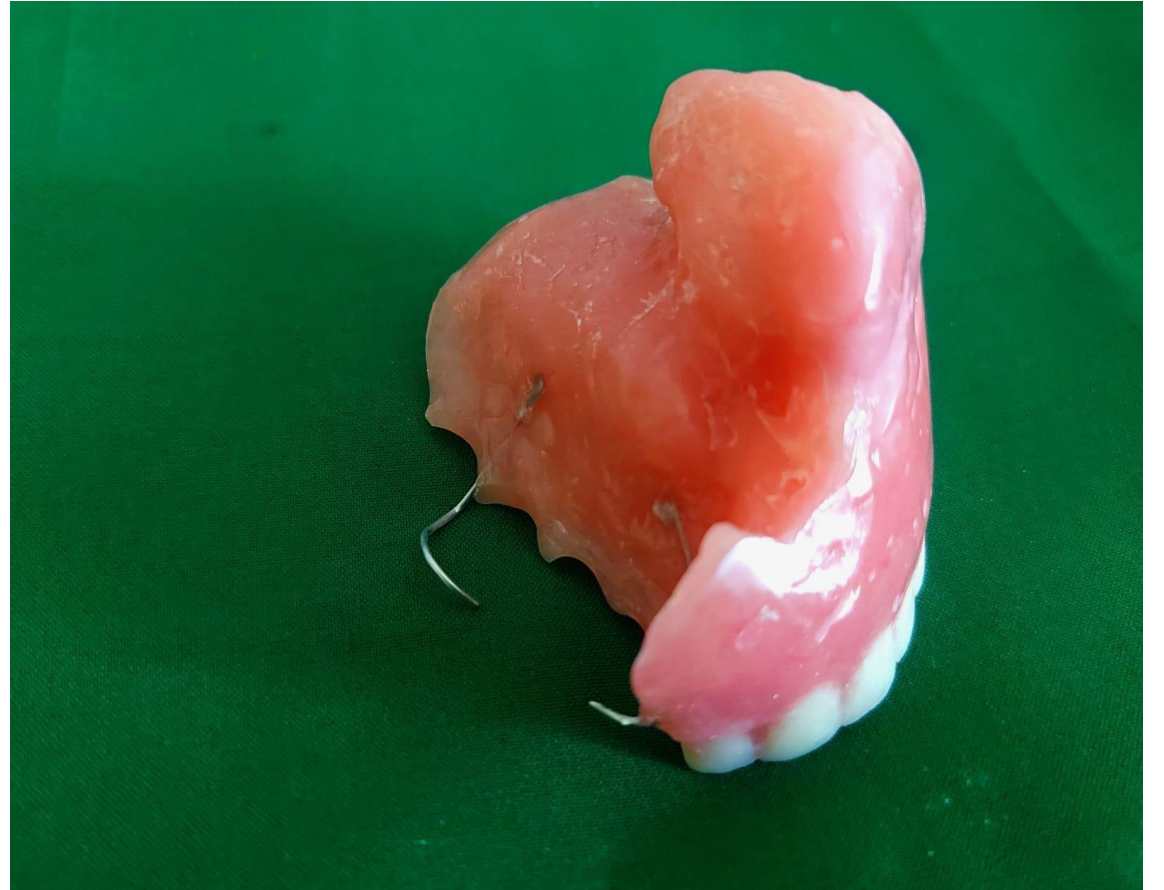
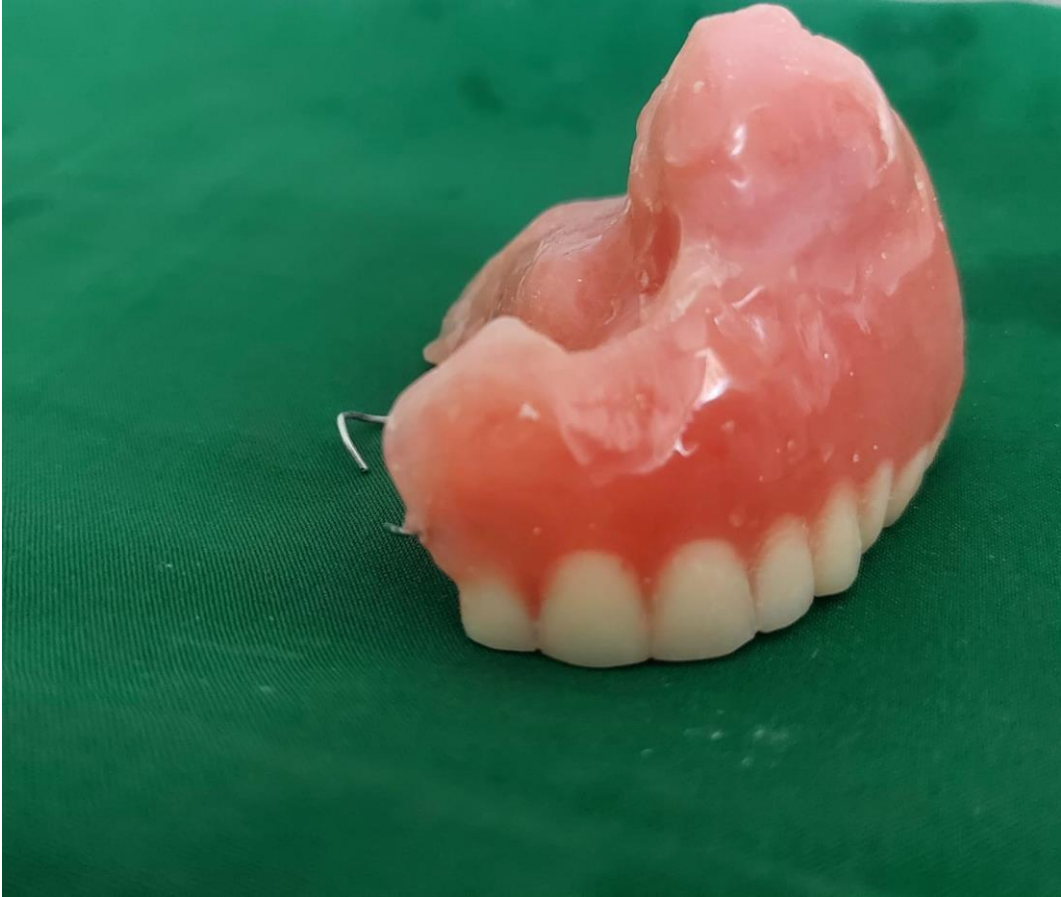DEWAXING



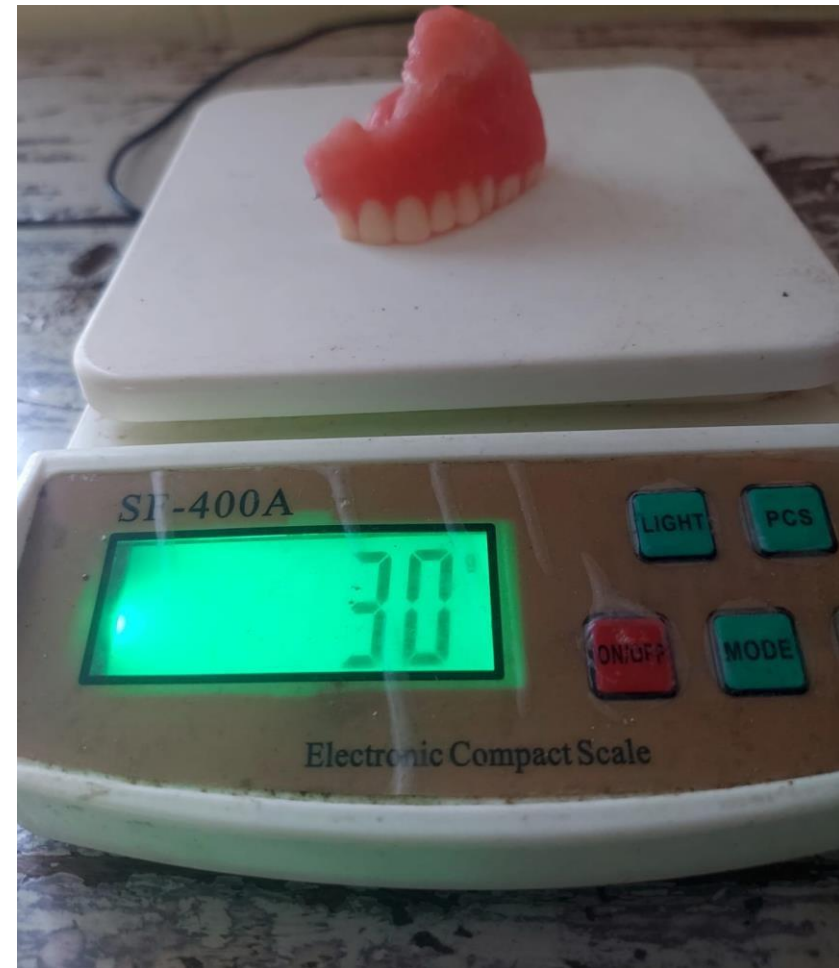**PACKING-DENTURE PROCESSING WITH  
ADDITION OF CRYSTALLIZED SALT**



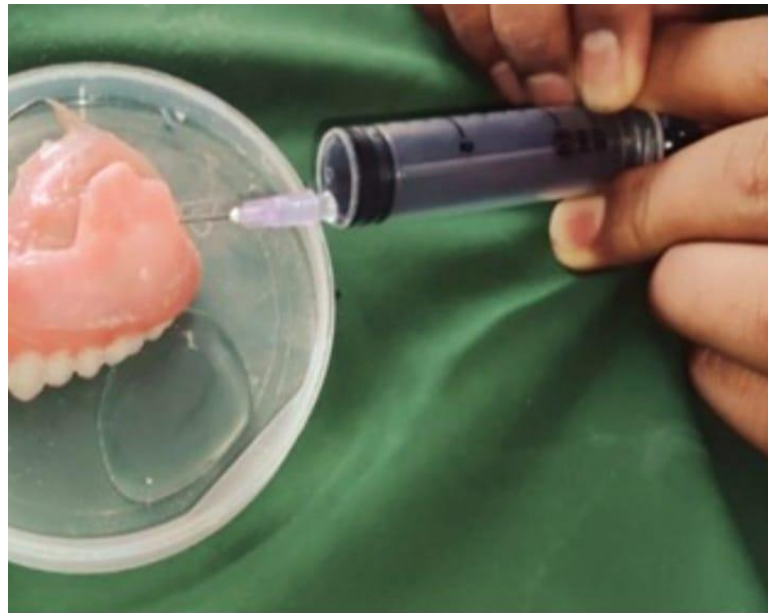**BENCH PRESS**



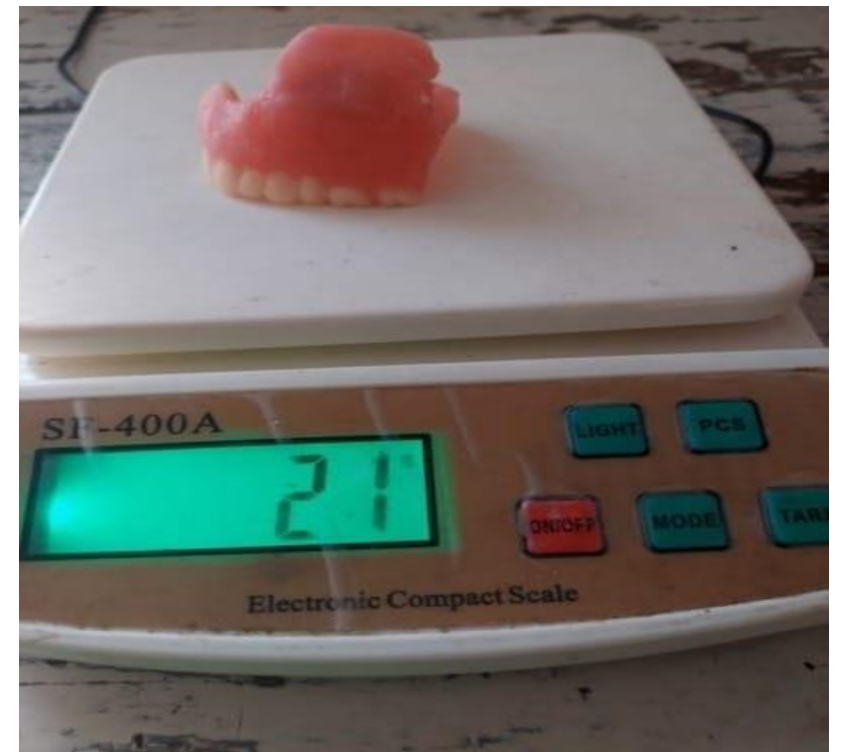**FINAL PROCESSED HOLLOW  
BULB OBTURATOR**



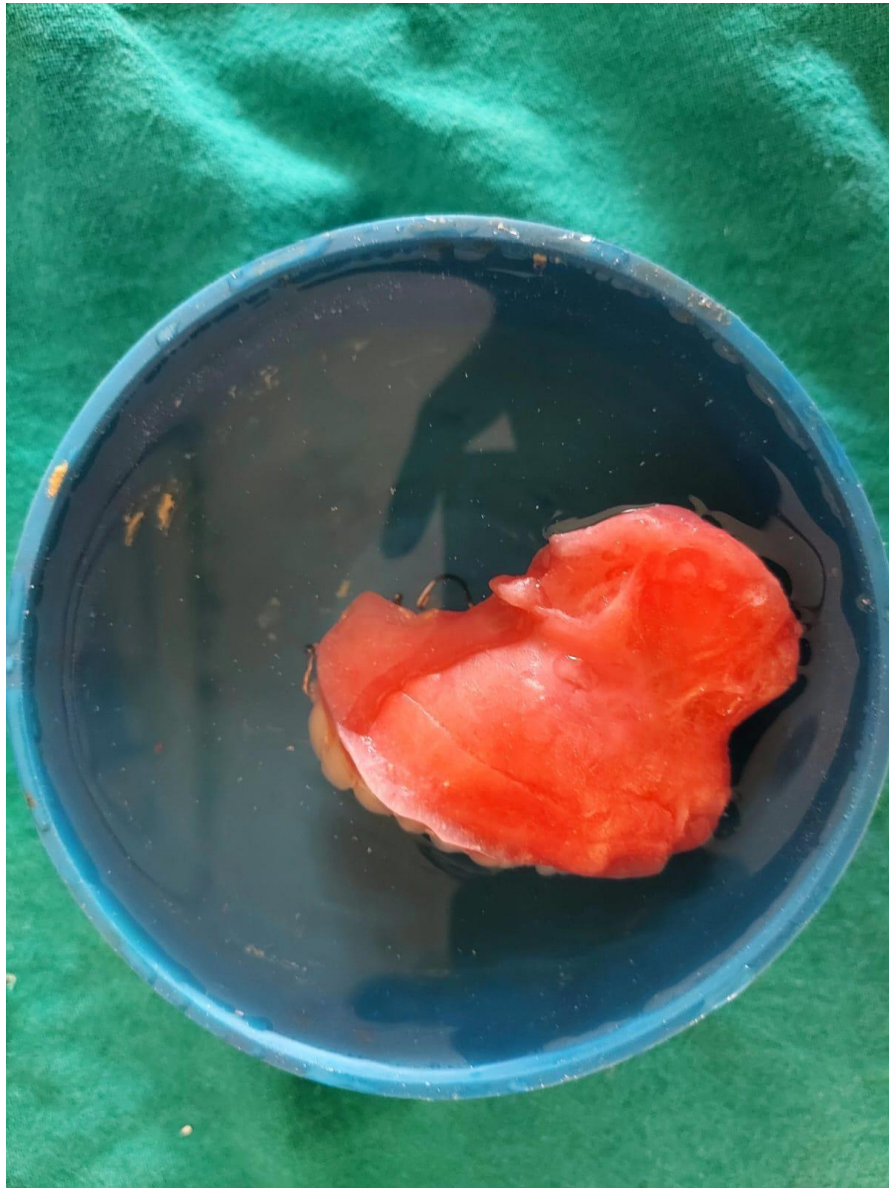PREWEIGHTED OBTURATOR  
BEFORE SALT REMOVAL



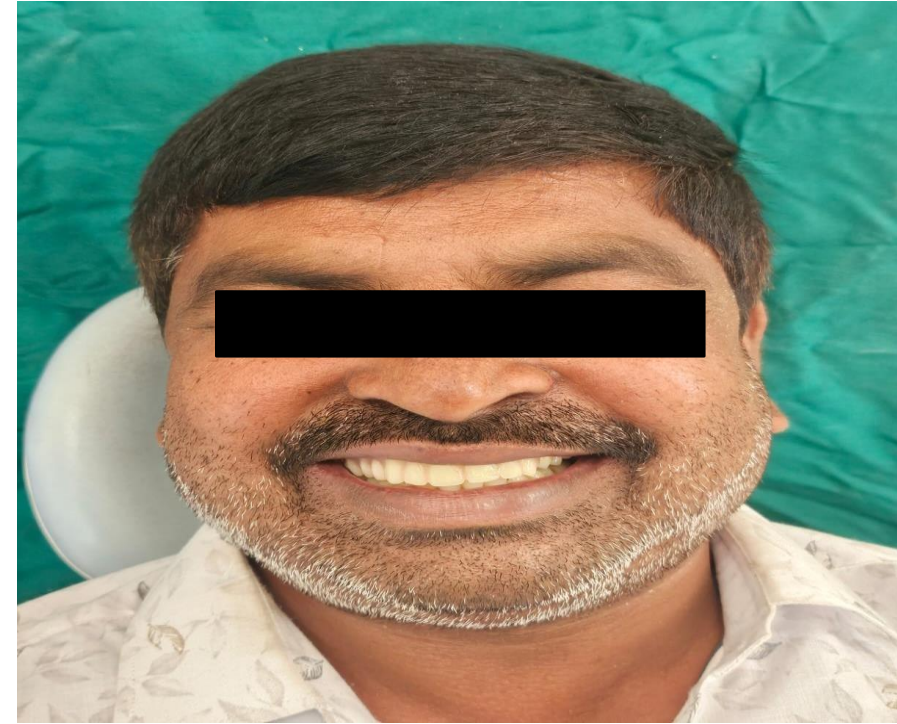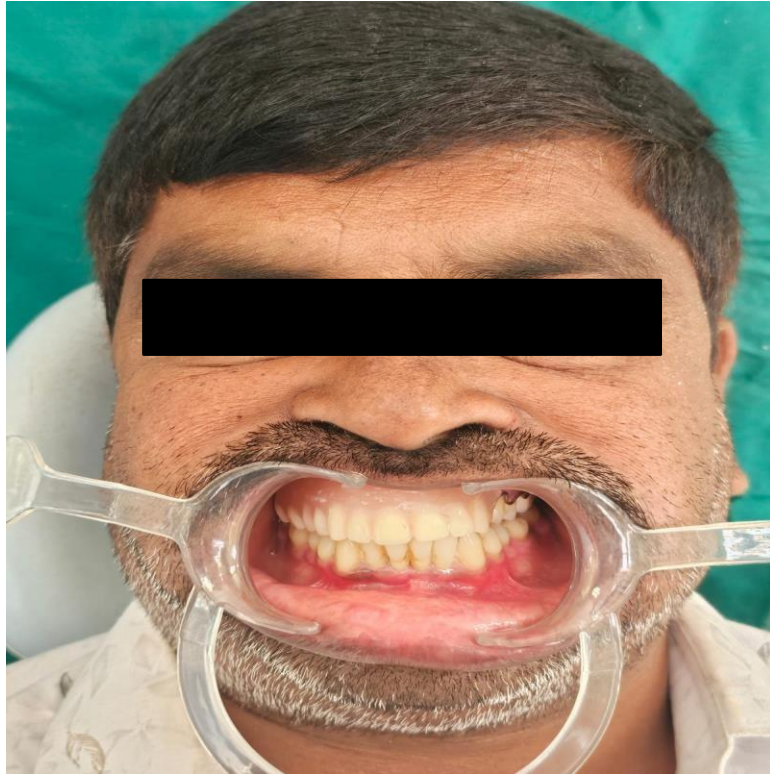FLUSHING OUT SALT  
CRYSTALS



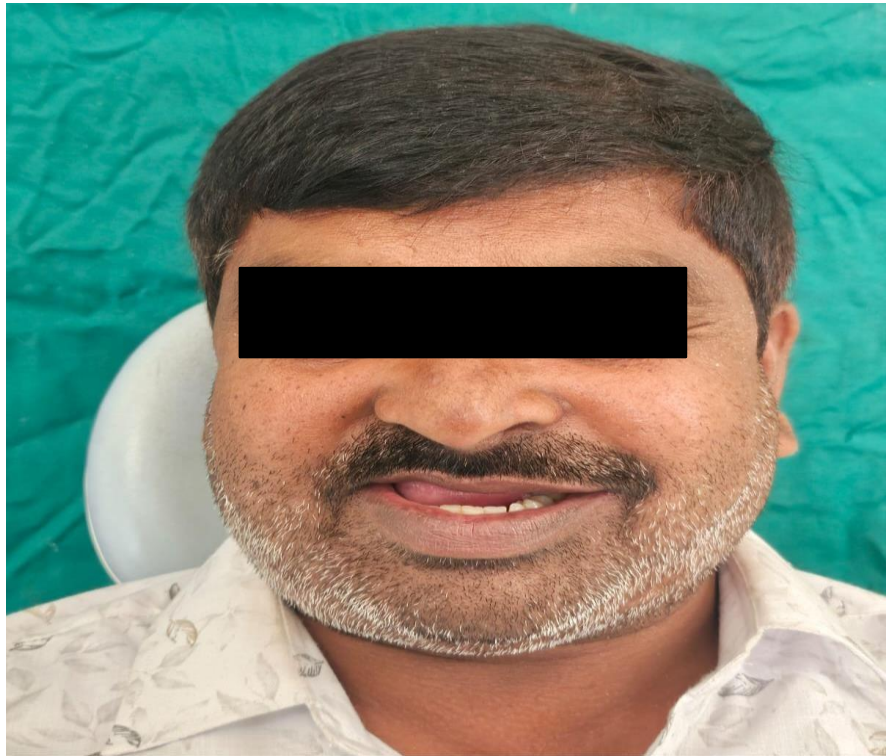POST WEIGHT OBTURATOR  
AFTER SALT REMOVAL



**FLOATING OF HOLLOW BULB  
OBTURATOR**



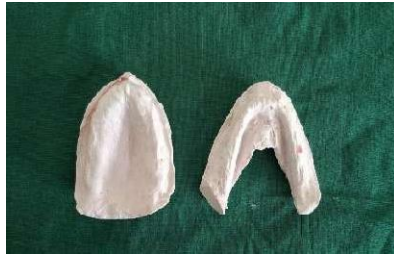**POST INSERTION-INTRORAL AND EXTRAORAL VIEWS**



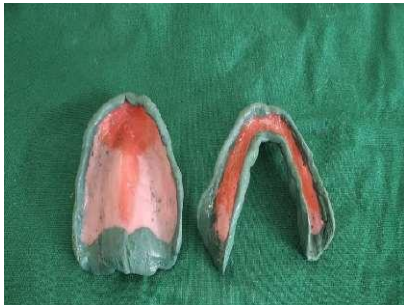**PREOPERATIVE-  
EXTRAORAL  
PHOTOGRAPH**

**POST OPERATIVE-  
EXTRAORAL  
PHOTOGRAPH**

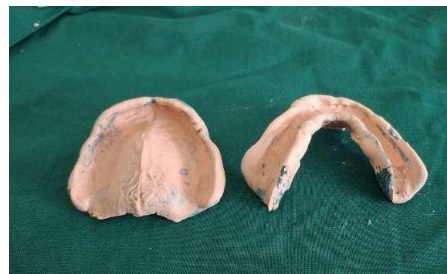**MESH REINFORCED DENTURE**



**PRIMARY CAST**

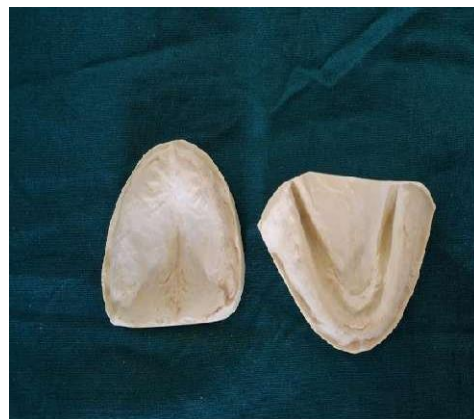

**BORDER MOLDING**

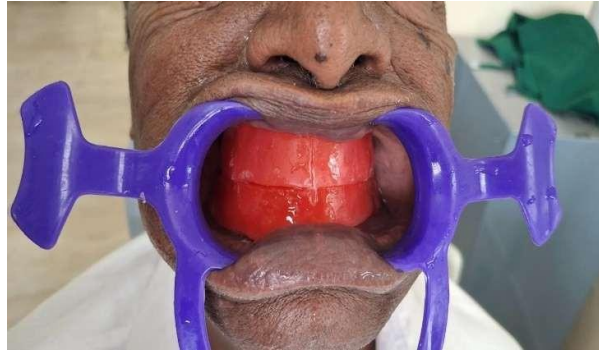

**SECONDARY**

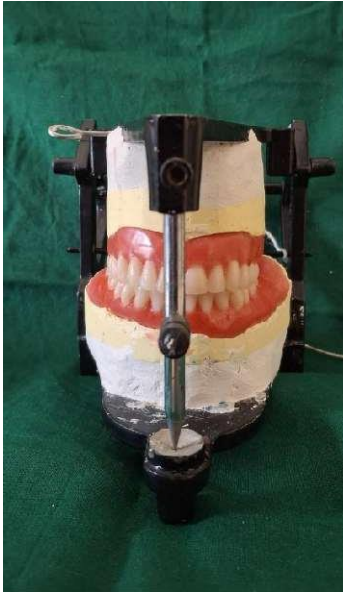**IMPRESSION**



**MASTER CAST**



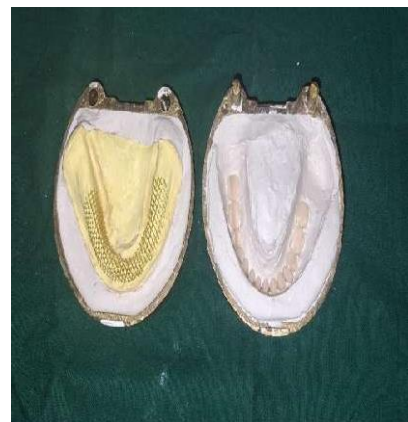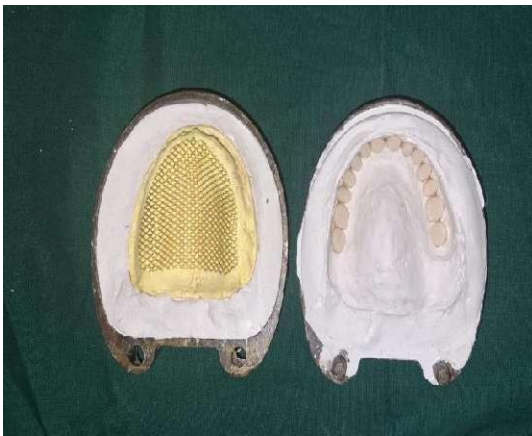**JAW RELATION**



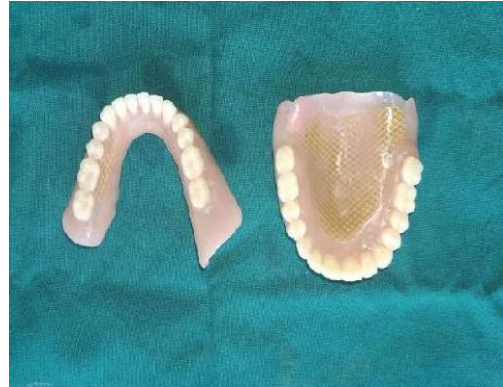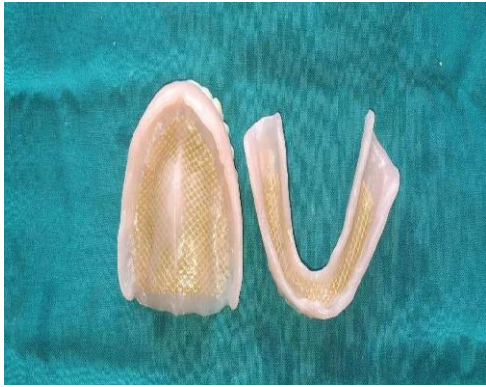
**ARTICULATION**



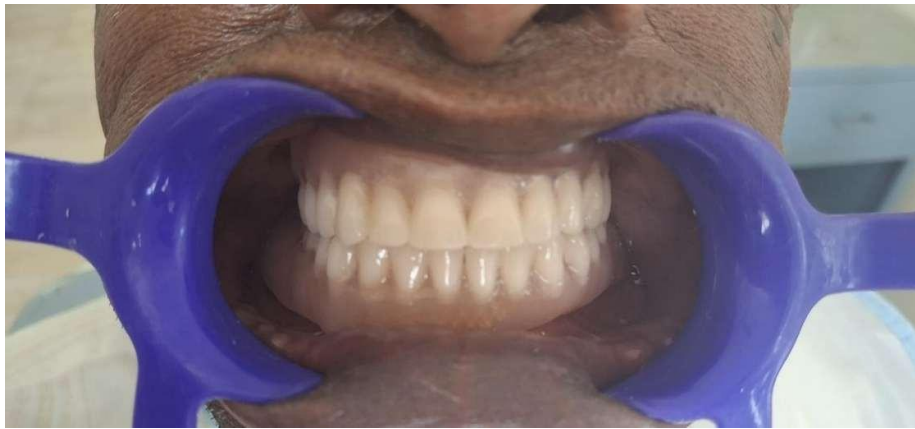**TRY-IN**



**PACKING ALONG WITH THE MESH IN  
MAXILLA AND MANDIBULAR CAST**



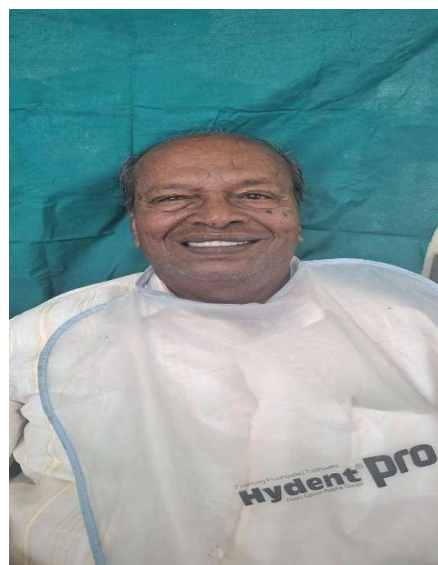**FINAL DENTURE ALONG WITH THE MESH**



**FINAL DENTURE INSERTION**

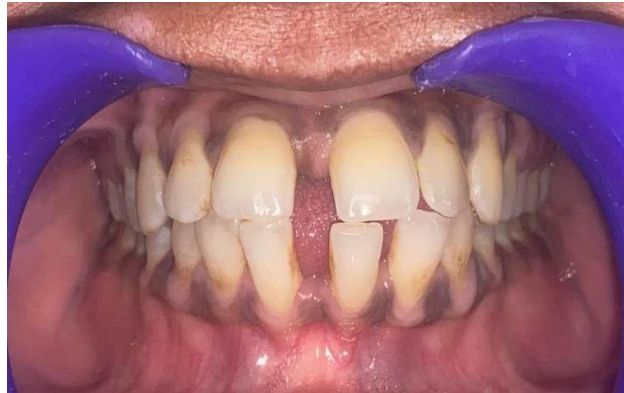

**PRE-TREATMENT**

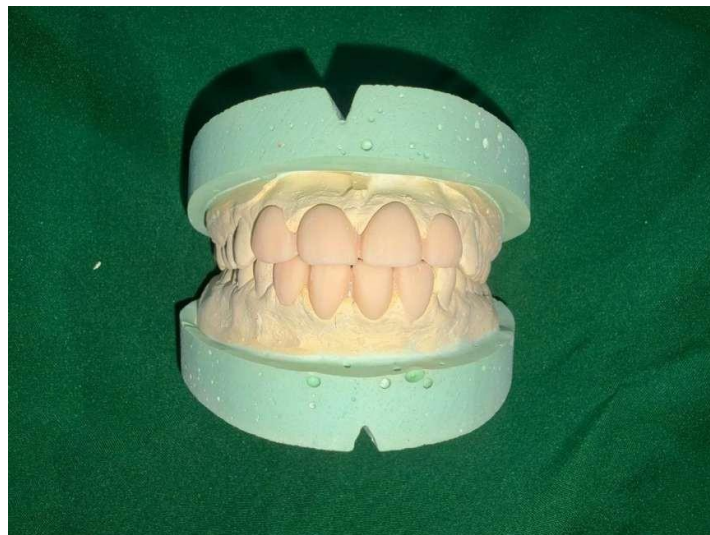


**POST-TREATMENT**

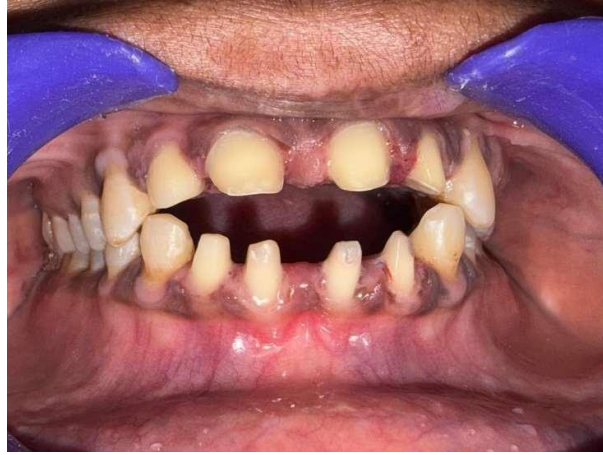## MIDLINE DIASTEMA CLOSURE



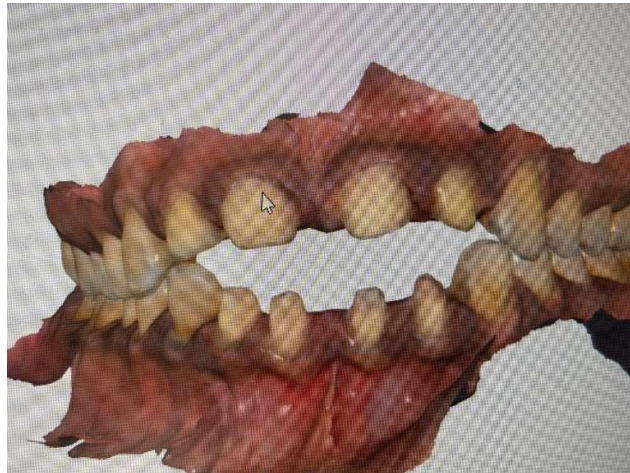
**PATIENT WITH COMPLAINT OF SPACING IN UPPER AND LOWER FRONT TOOTH REGION**



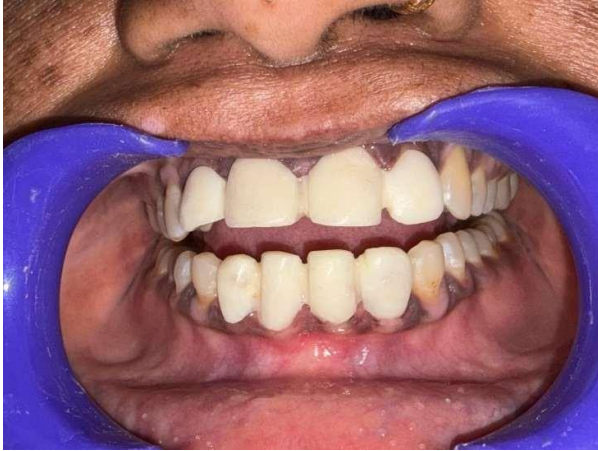**MOCK UP**



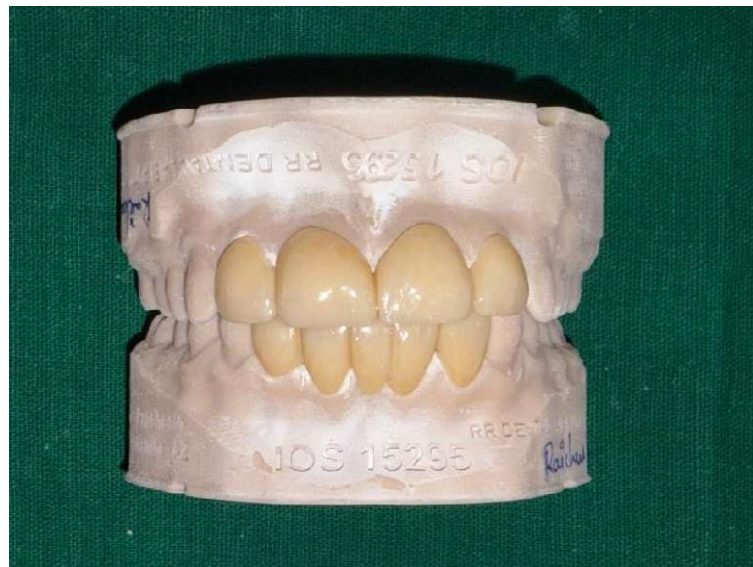
**TEETH PREPARATION**



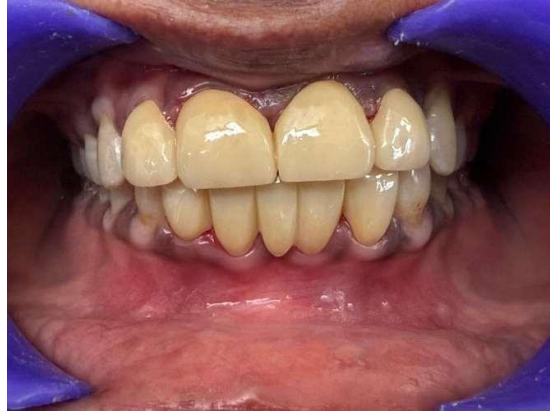**INTRAORAL SCANNING OF PREPARATIONS**



**PROVISIONAL RESTORATIONS GIVEN**



**FINAL PROSTHESIS**

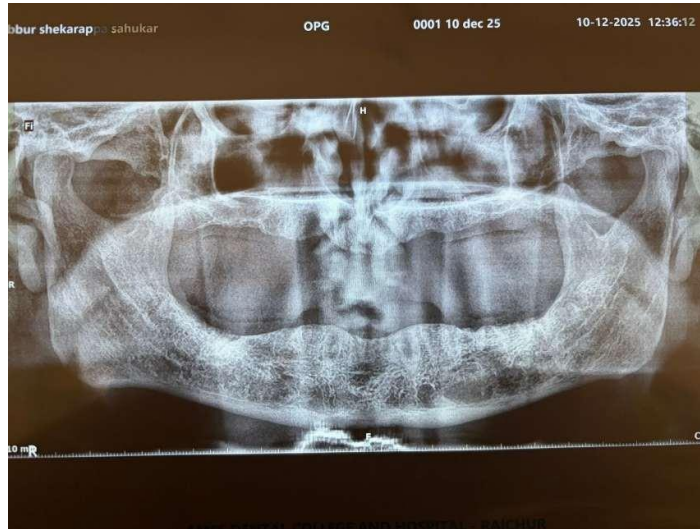


**FINAL PROSTHESIS CEMENTATION DONE**

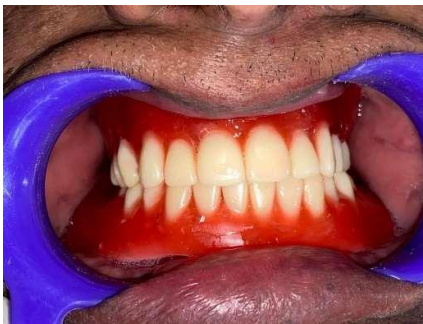

**POST-TREATMENT – MIDLINE DIASTEMA CLOSURE**

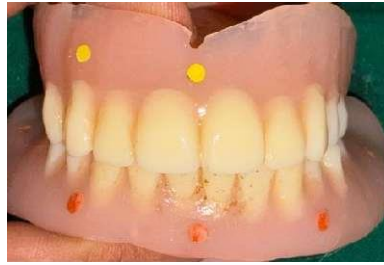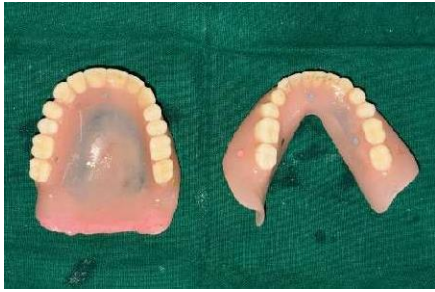# SURGICALLY GUIDED FULL MOUTH IMPLANT REHABILITATION



**PREOPERATIVE OPG OF THE  
PATIENT**



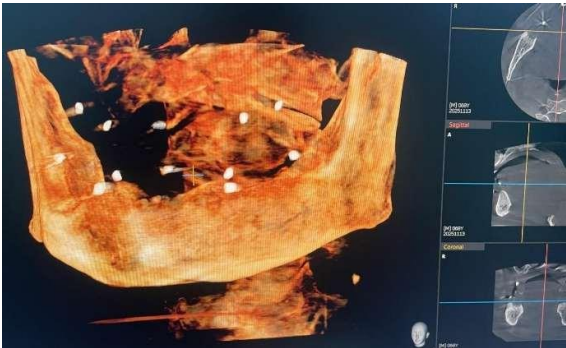**CONVENTIONAL DENTURE TRY-IN    INSERTION**



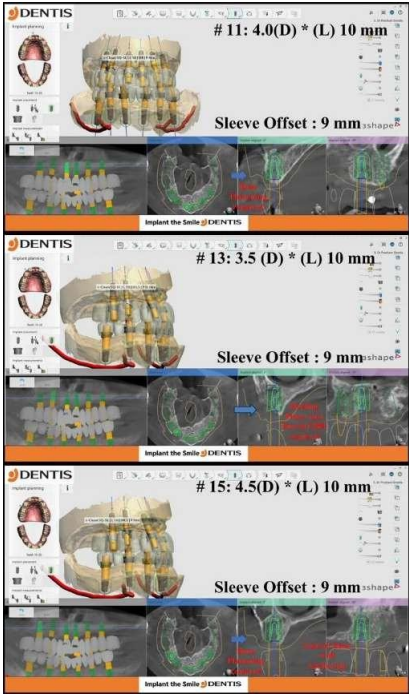
## DENTURE MARKED WITH GUTTA PERCHA POINTS FOR CBCT SCANNING



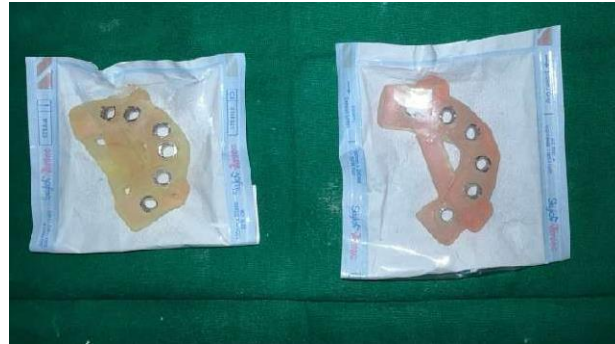# CBCT SCANNING OF THE PATIENT USING DUAL SCAN TECHNIQUE



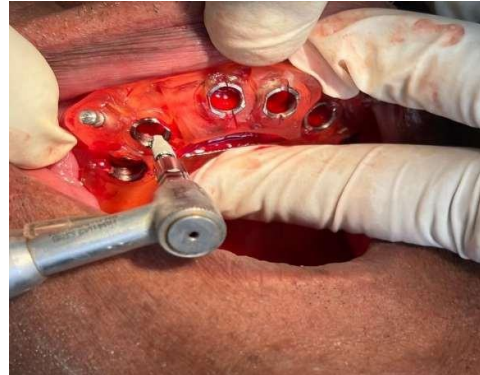
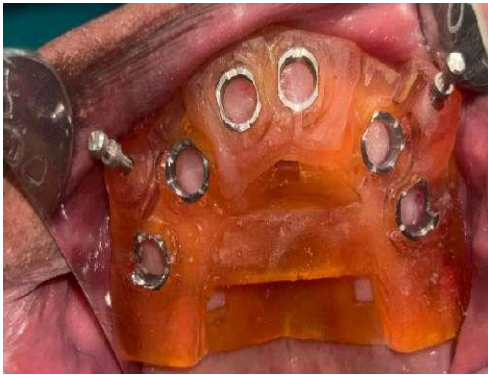**CBCT SCAN**



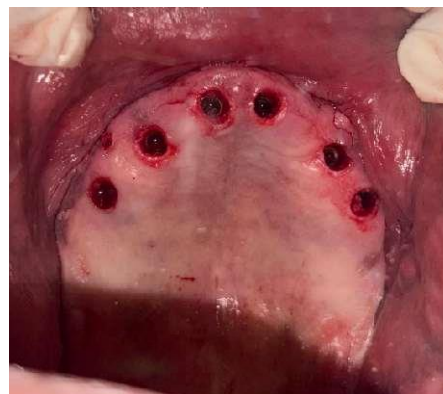**IMPLANT PLANNING DONE ACCORDING TO CBCT SCAN**



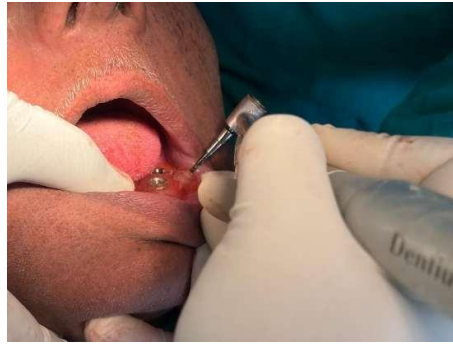**SURGICAL GUIDES**



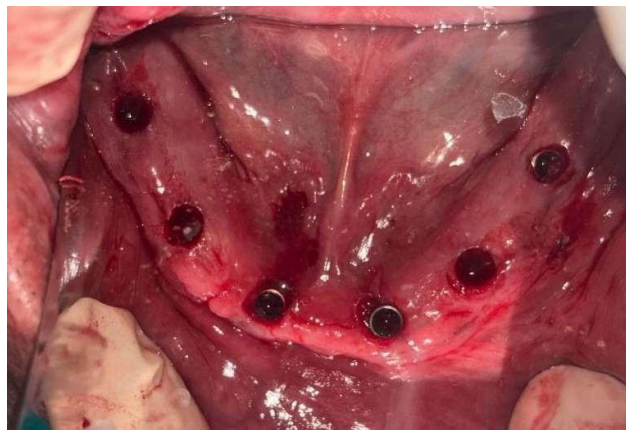
**SURGICAL GUIDE STABILIZED IN PATIENT MOUTH  
AND IMPLANT PLACEMENT**



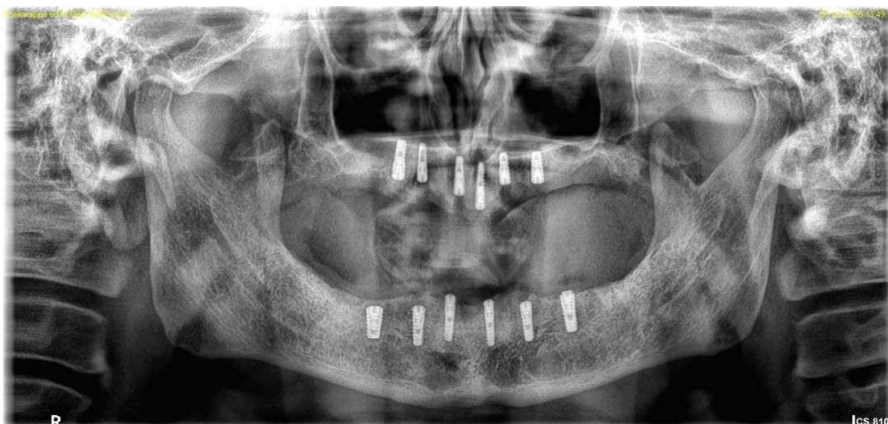
**MAXILLARY ARCH AFTER IMPLANTS  
PLACEMENT**



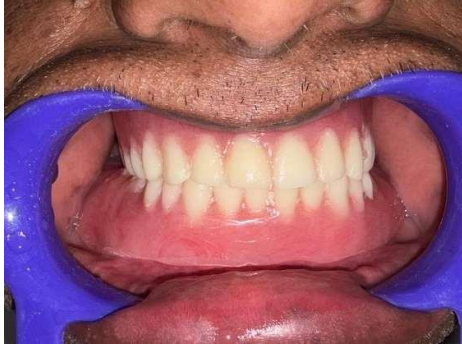**IMPLANT PLACEMENT IN MANDIBLE**



**MANDIBULAR ARCH AFTER IMPLANT PLACEMENT**



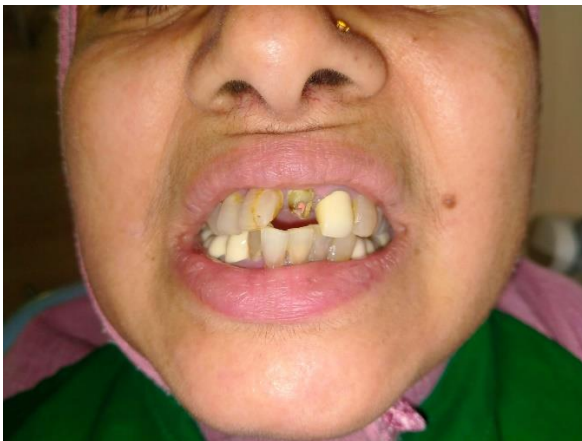**POST TREATMENT OPG OF THE PATIENT**

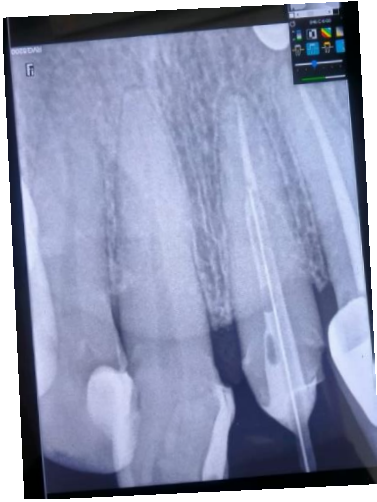


### **INTERIM PROSTHESIS FABRICATED AND DELIVERED**

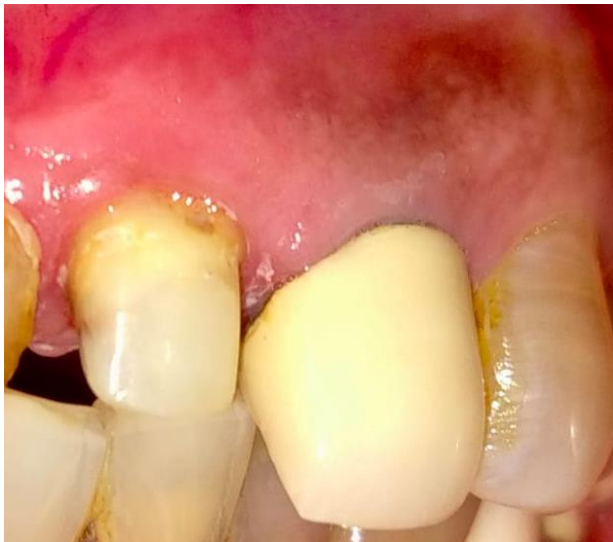#### Post and Core

- Name :- Sana sultana
- Age :- 40 years
- Chief complaint:- Dislodged crown in upper front teeth.
- Treatment plan:- post and core is done





Fibre post place w.r.t 21



Composite buildup and tooth preparation done w.r.t 21

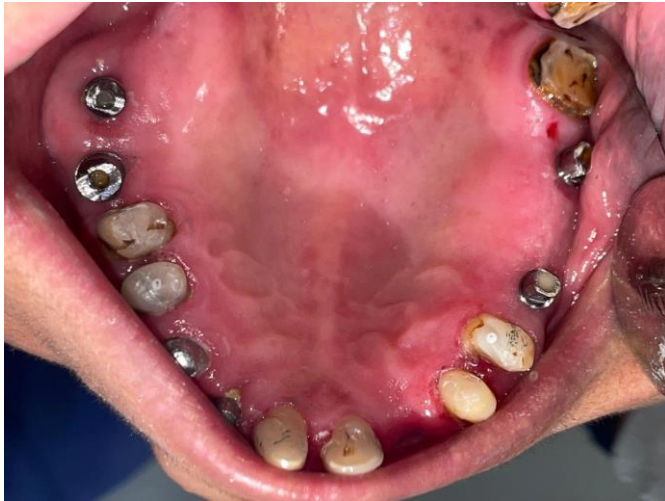## **Full mouth Rehabilitation**

Name:- Lakshmi

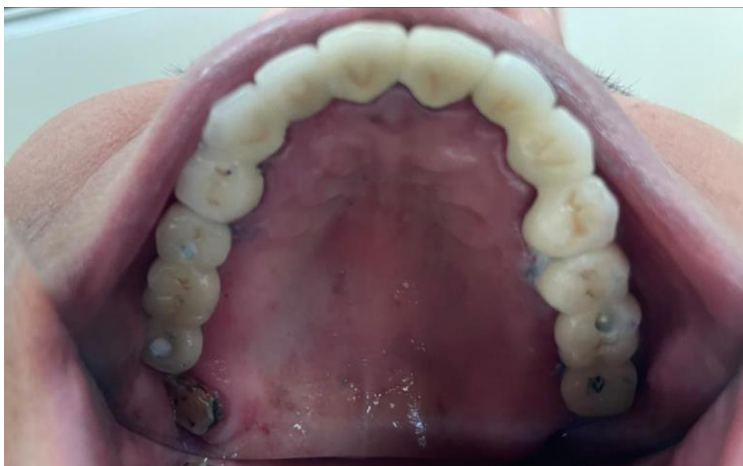Age:- 52

Chief complaint :- Patient complaints of missing teeth w.r.t upper 12,13,16,17,25,27

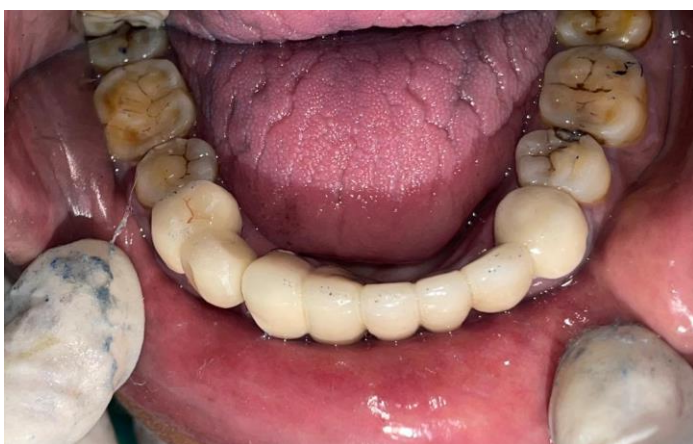Treatment plan:- Implant-supported full-mouth rehabilitation



Implant placement done



PFM cement retained prosthesis

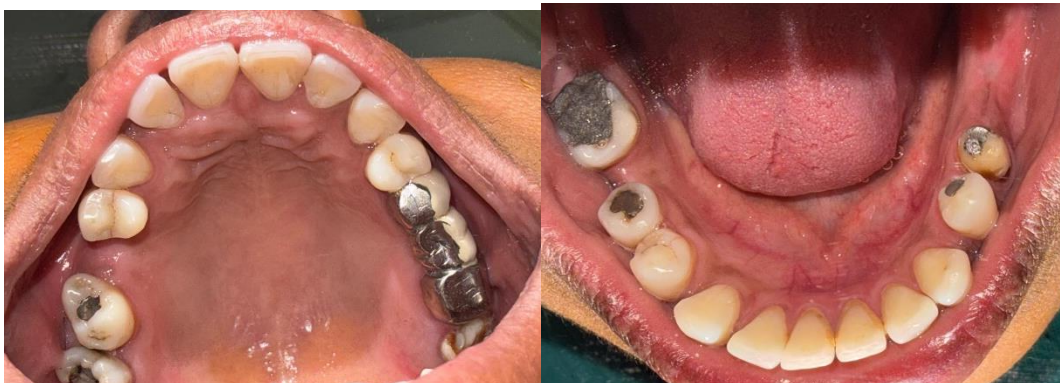

PFM crowns place w.r.t 33 and 34

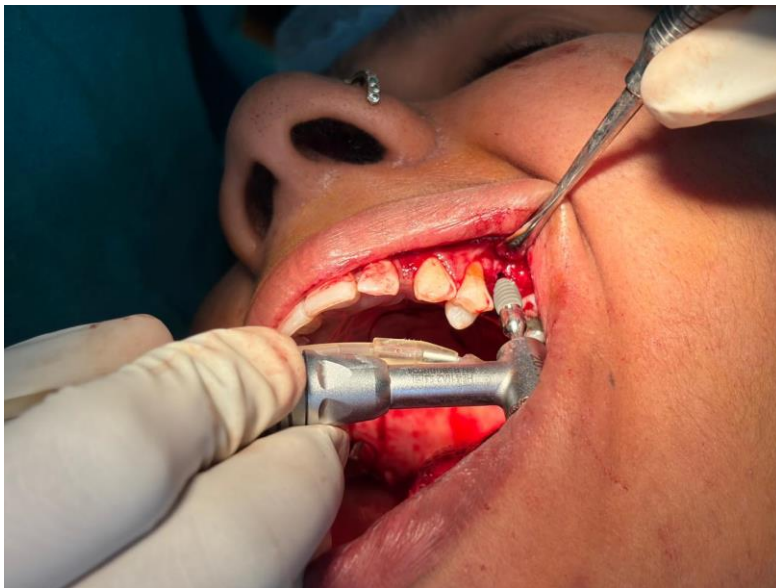
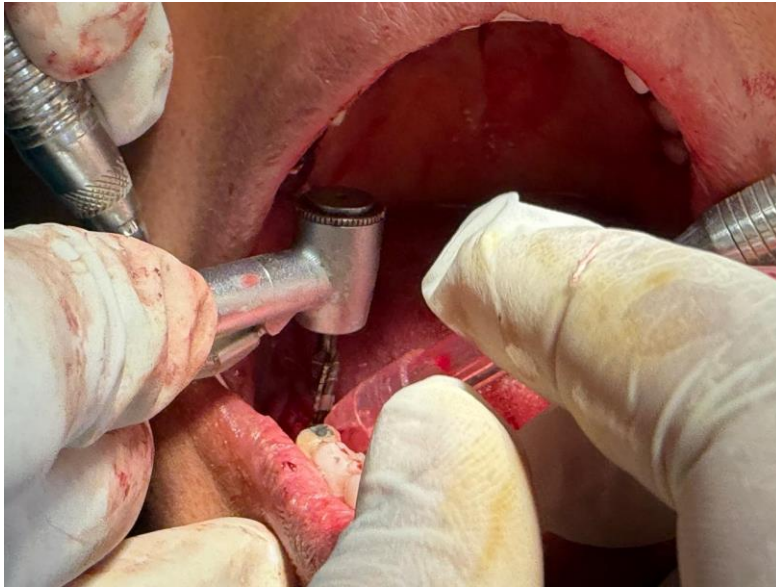
## Multiple Implants

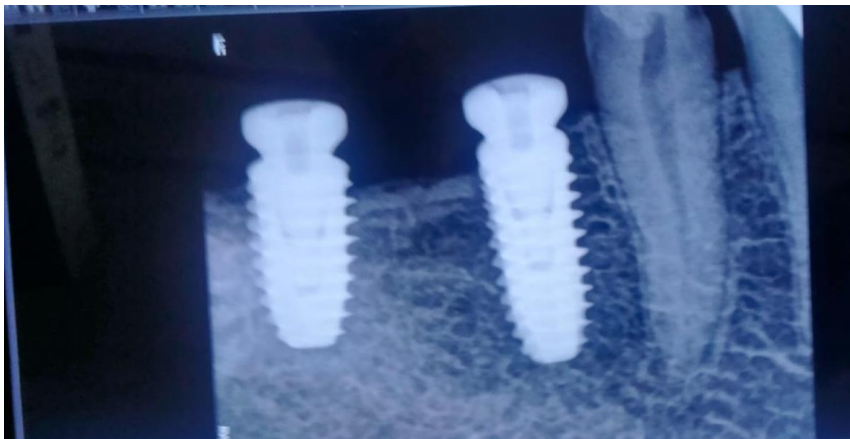
- Name:- Asiya banu
- Age :- 35
- Chief complaint:- missing multiple teeth in the upper and lower back region of the jaw
- Treatment plan :- implants placement w.r.t 15,46 47



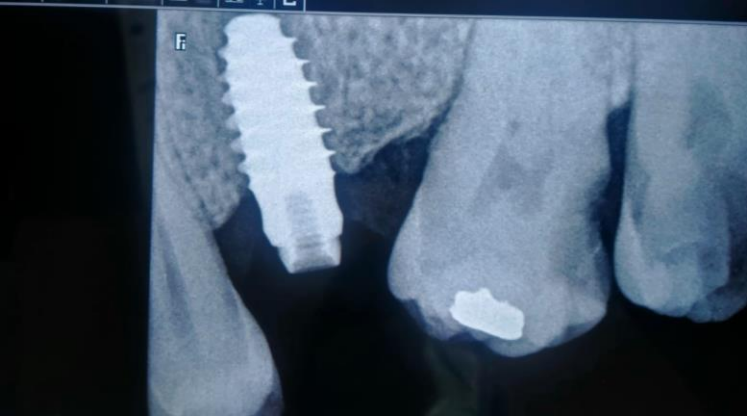## Maxillary and mandibular edentulous spaces



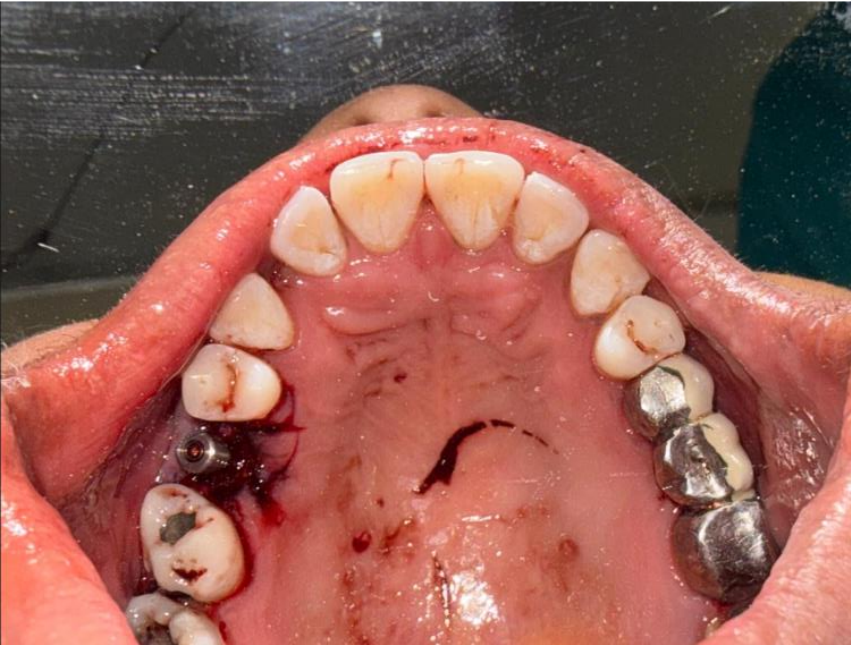## Maxillary implant placement



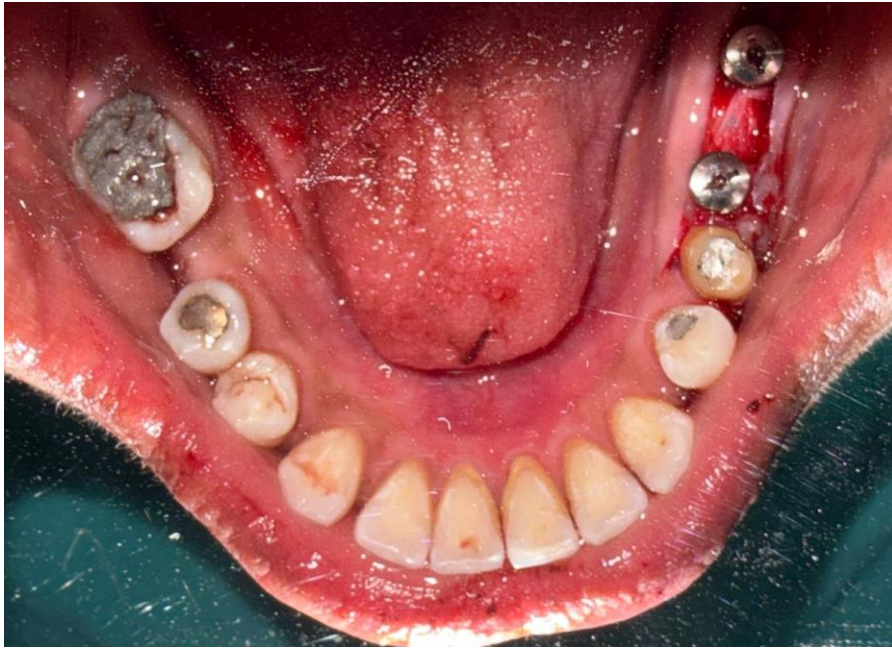RVG of Mandibular Implant Placement



RVG of Maxillary Implant Placement



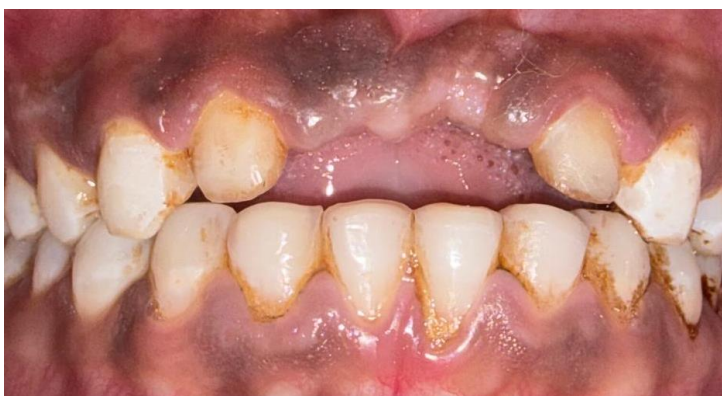Intraoral image of Maxillary implant



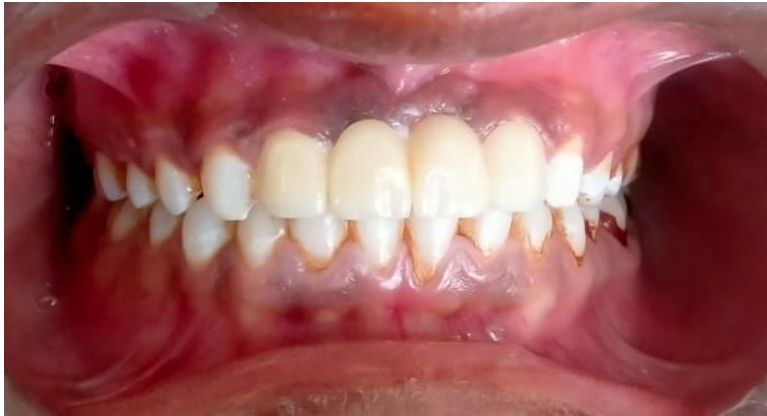Intraoral image of Mandibular Implant

### Anterior zirconia

- Name :- Rangayya
- Age :- 20 years
- Chief complaint:- patient complains of missing anterior teeth in the upper front region of the jaw.
- Treatment plan :- zirconia crown was placed w.r.t 12,11,21,22



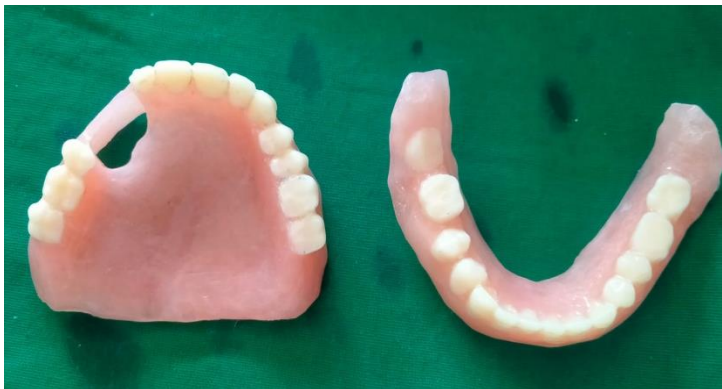Missing Anterior teeth



Zirconia Fixed Partial Denture

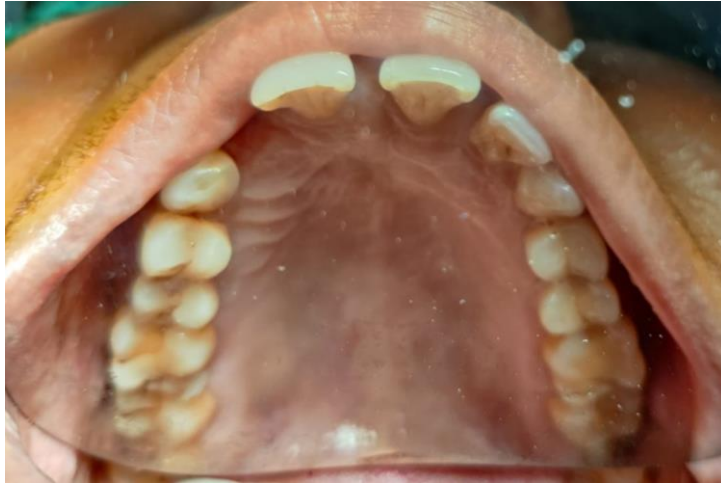## Cucil Denture

- Name :-Begum
- Age :-70
- Chief complaint:- missing teeth w.r.t upper and lower front and back regions of the jaw

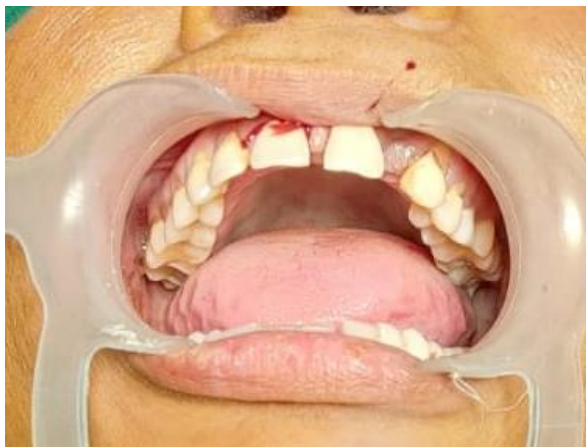

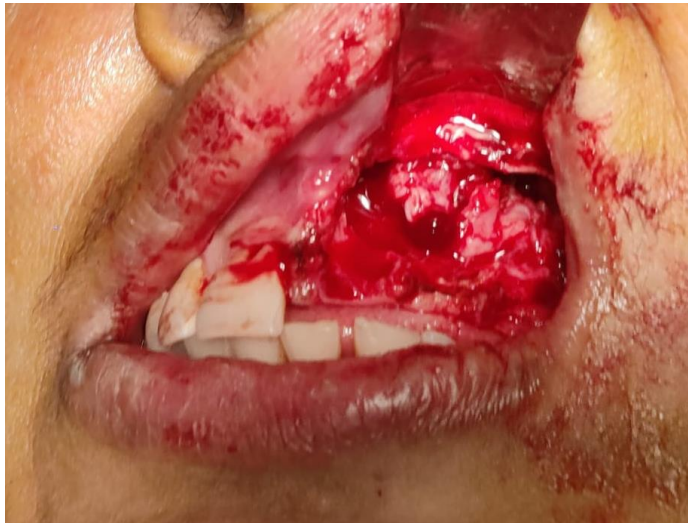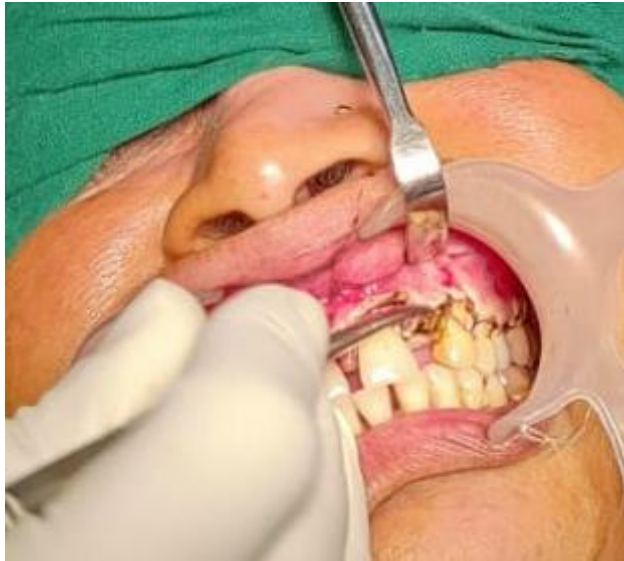- Name :- Fathima
- Age:-45
- Chief complaint: Patient complains of missing teeth with respect to the upper front region of the jaw
- Diagnosis:-Radicular cyst

- Treatment Plan:- excision of cyst along with teeth which are involved

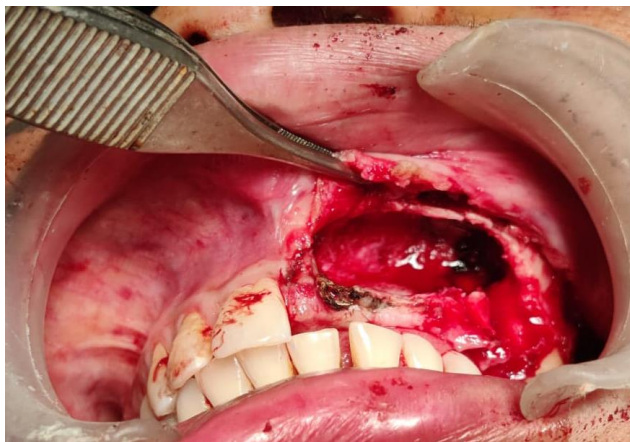


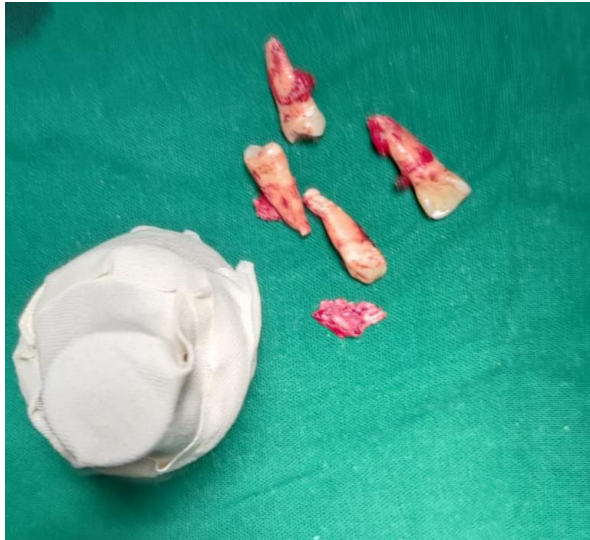Intraoral Photograph with missing 22





Cyst Excision





Extraction of teeth involving cyst and Cyst sent for biopsy  
Evaluation

## Flexible denture

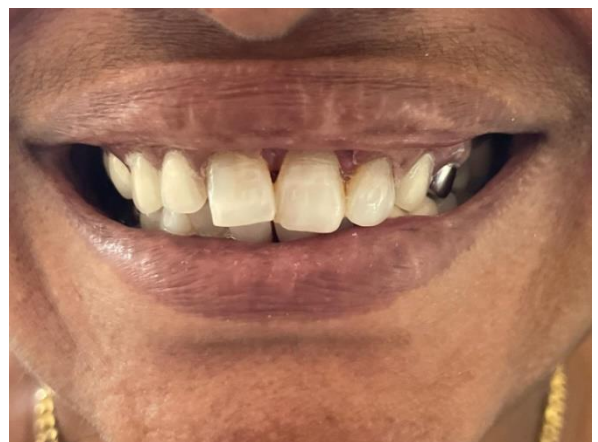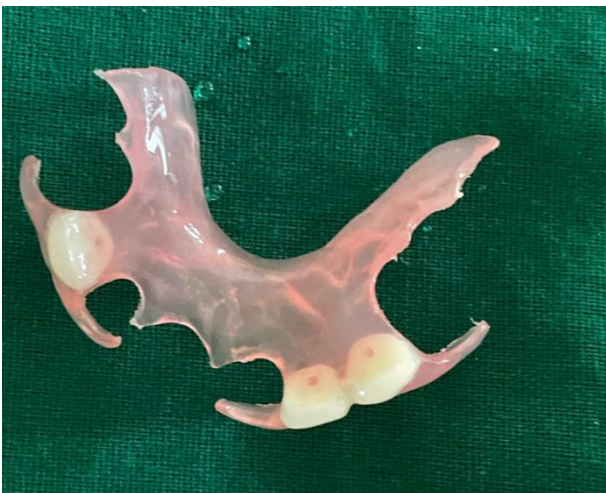Pt name: Savirthri

Age:62 years

Missing tooth irt 23, 12, and 13

Advised removal of partial denture

Treatment done: flexible denture



# Anterior zirconia crown

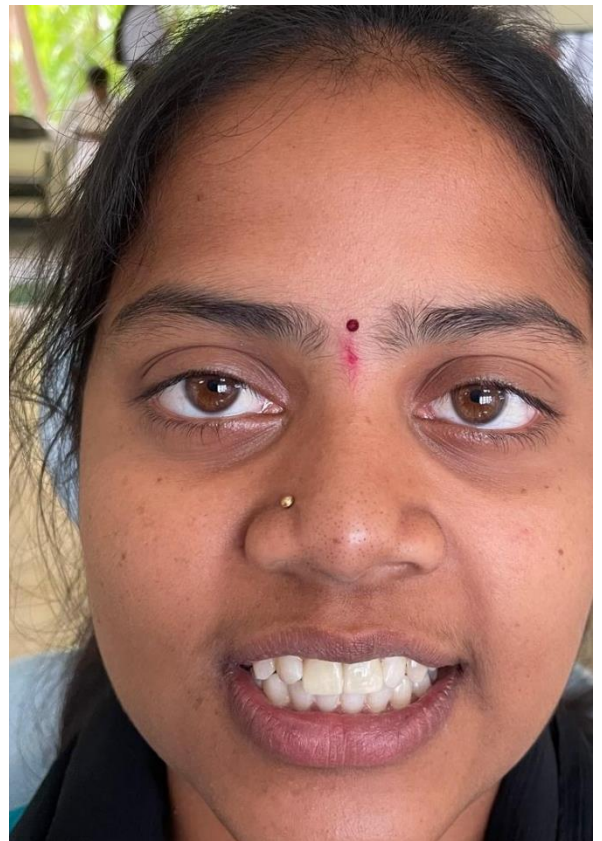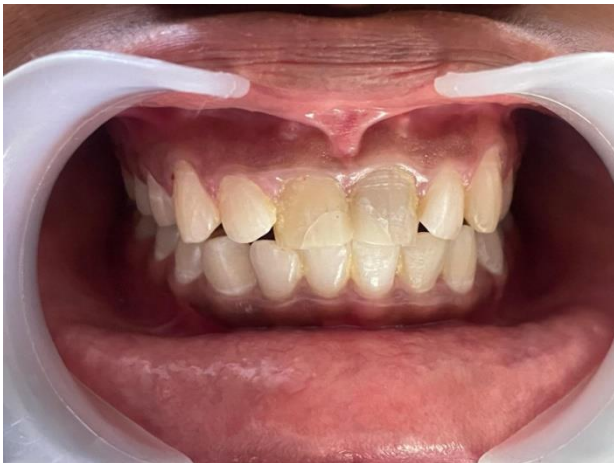Pt name: pushpalatha

Age :24yearsFemale

Discolouration of 11,21

Advised crown irt 11,21

Treatment done :Zirconia crown irt 11,12



# Neutral-zone in a complete denture

patient name: Padamma

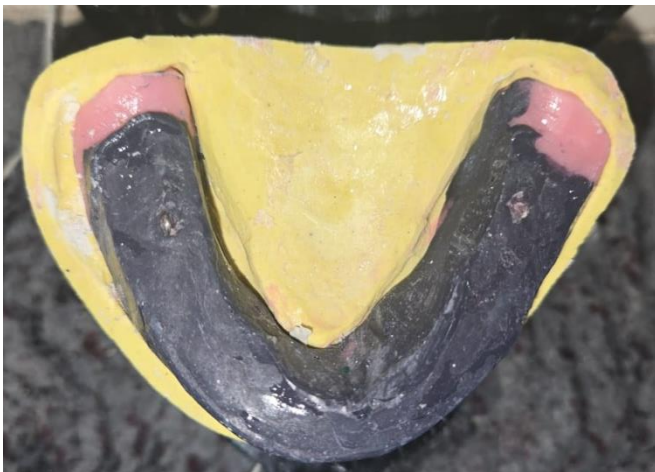age:40 years



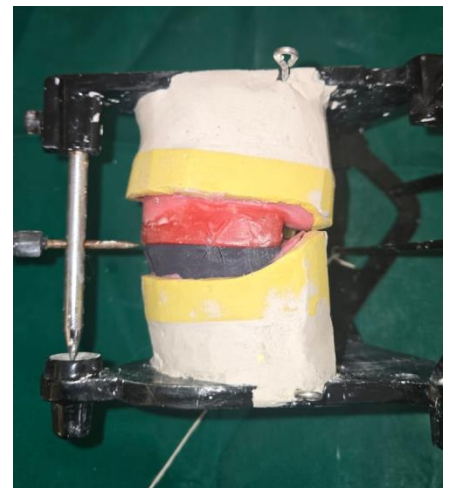
1.Master cast



2.Occlusal rims and metal retentive loops



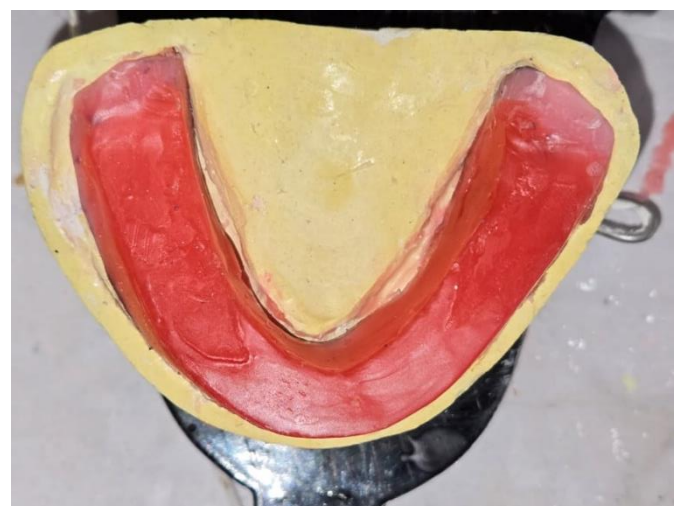3.Neutral zone recorded with admixed compound



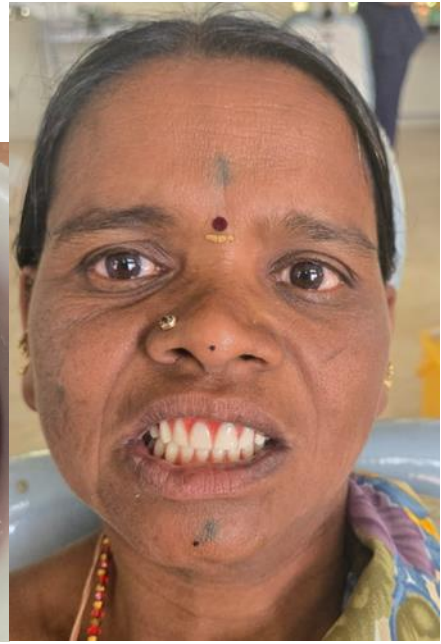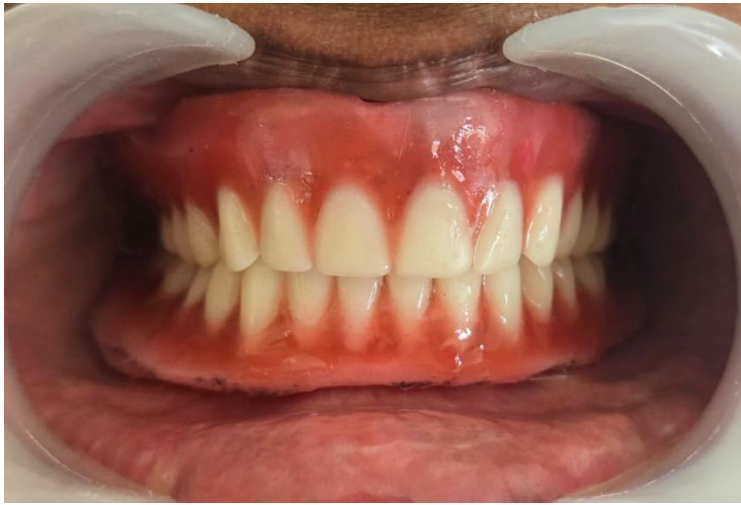4.Mounted casts



5.Matrices of denture space made using silicone putty



6.Admixed compound replaced with wax



Try it done using wax dentures

### **Anterior zirconia crown**

Patient name - Shankar

Procedure done - Anterior Zirconia w.r.t 21

