

DEPARTMENT OF
ORTHODONTICS AND
DENTOFACIAL ORTHOPÆDICS

SPECIAL CASES

PATIENT 1

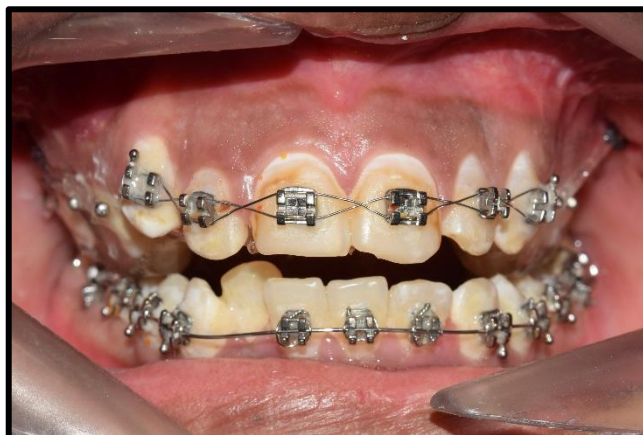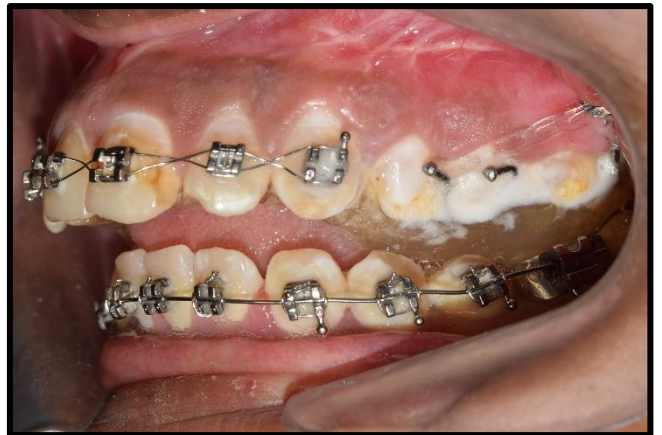
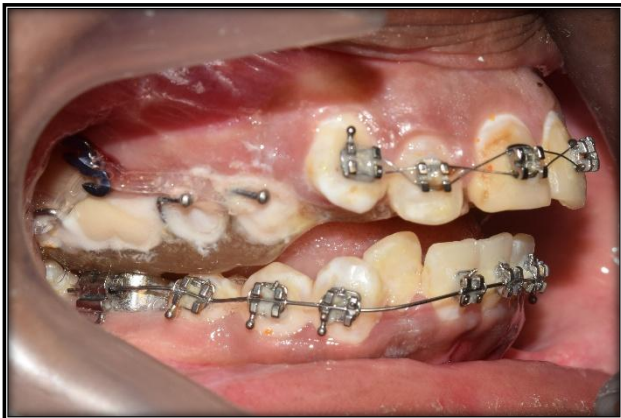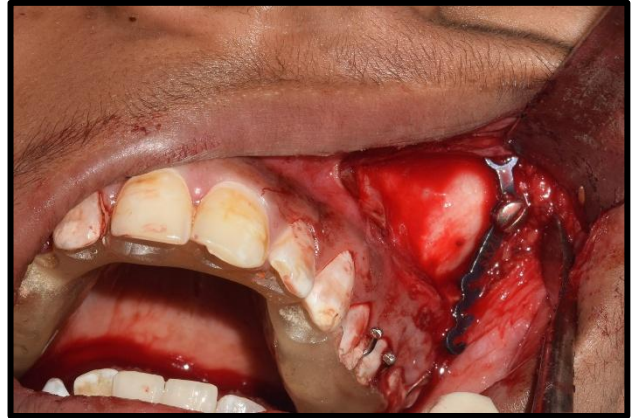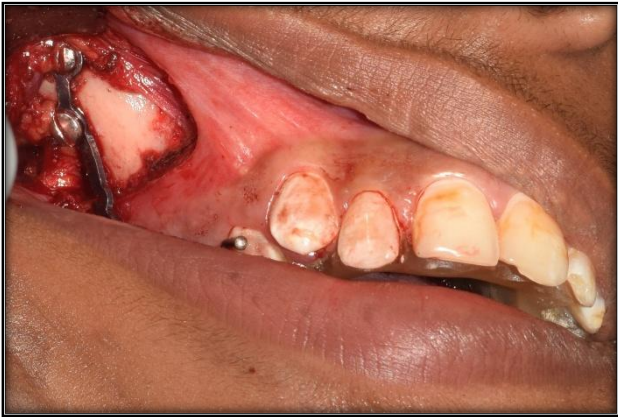PATIENT NAME : ABHINAYA

AGE / SEX : 23 / Female

OP NUMBER: 19859

MALOCCLUSION : Skeletal open bite

MECHANICS : Skeletal anchorage system Y plate placed for posterior intrusion



PATIENT 2

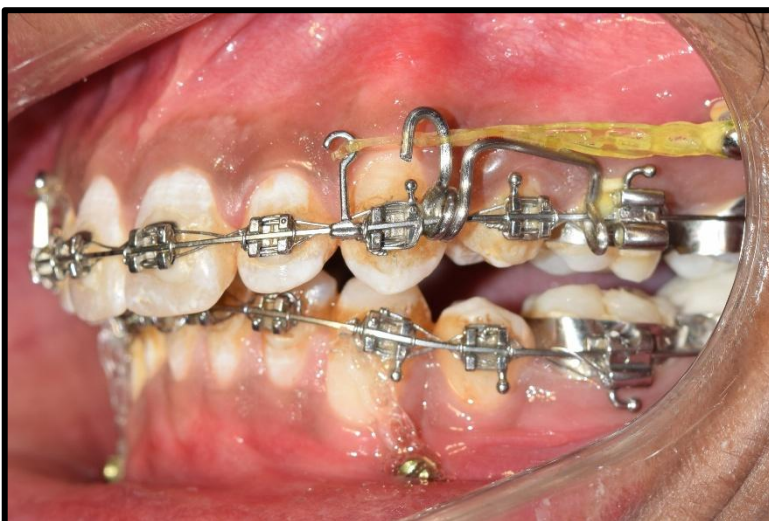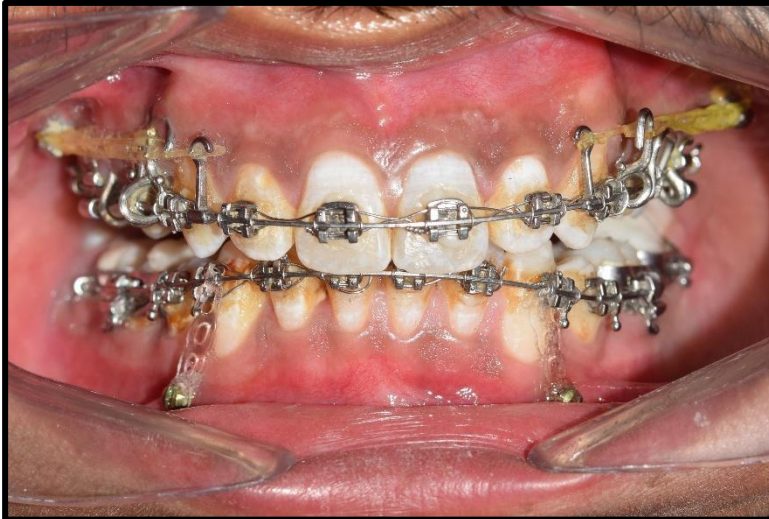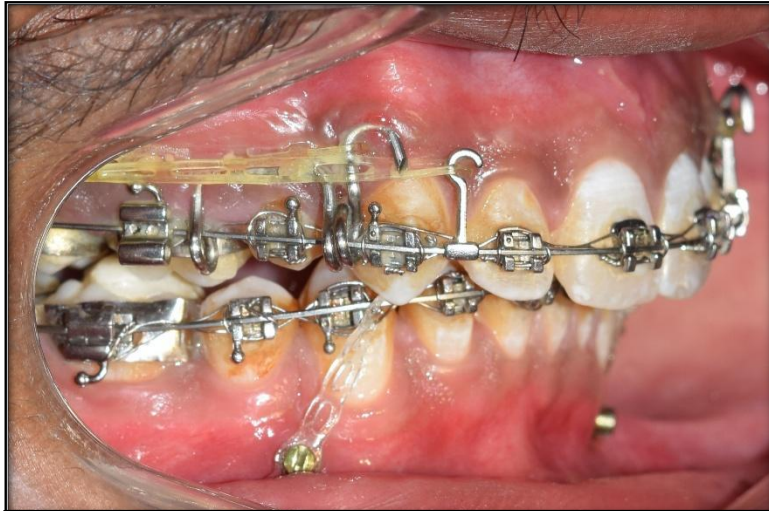PATIENT NAME : PRAVEEN

AGE / SEX : 24 / Male

MALOCCLUSION : Class 2 division 1

MECHANICS : Implant supported distalization

OPD NO - 19859



PATIENT 3

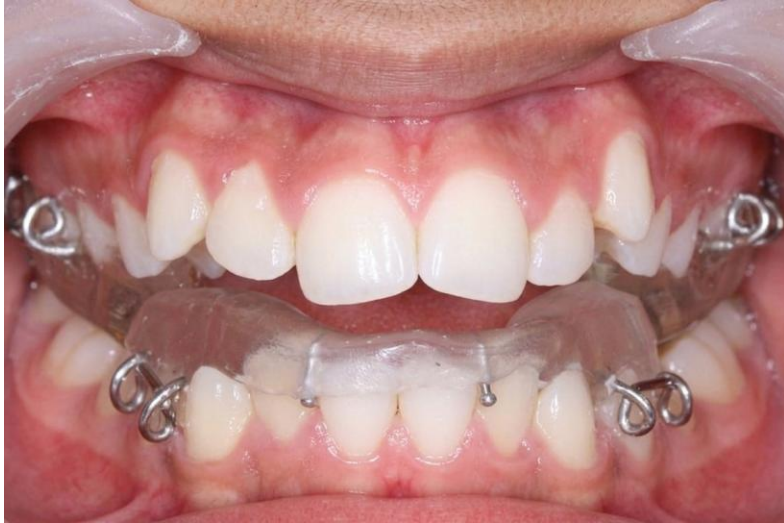NAME: KAILASH

AGE/SEX: 14/M

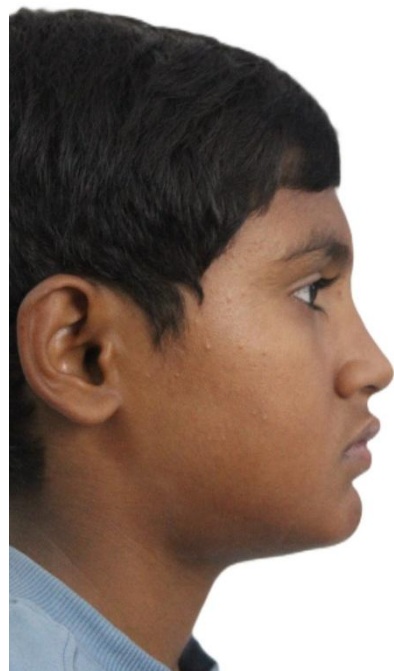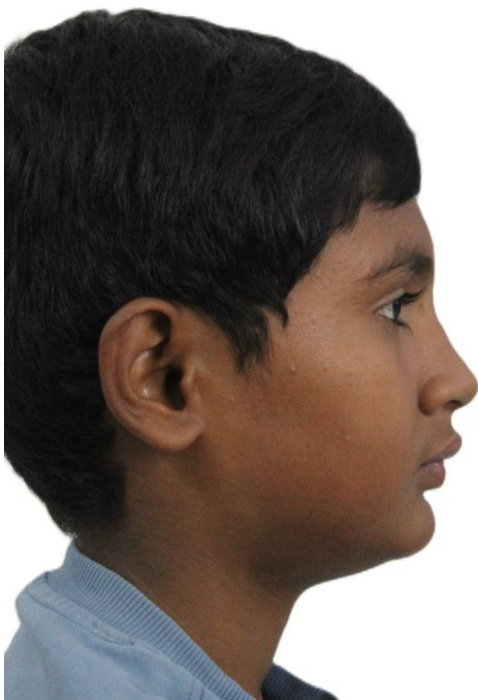MALOCCLUSION : Class 2 division 1

OPD no: 18142

Twin block appliance for mandibular advancement



Positive VTO



PATIENT 4

NAME: SHANTAMURTHY

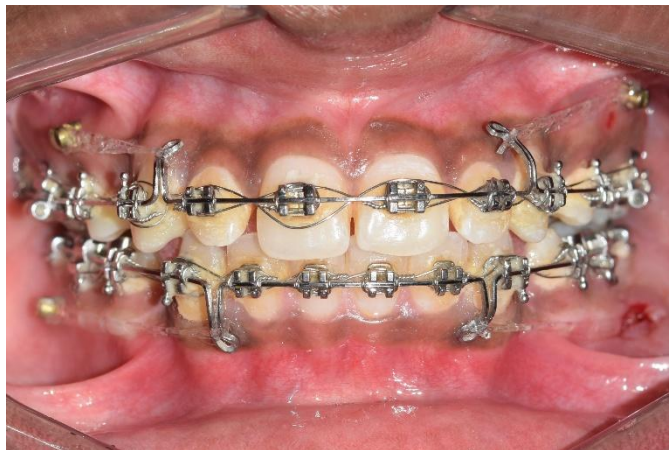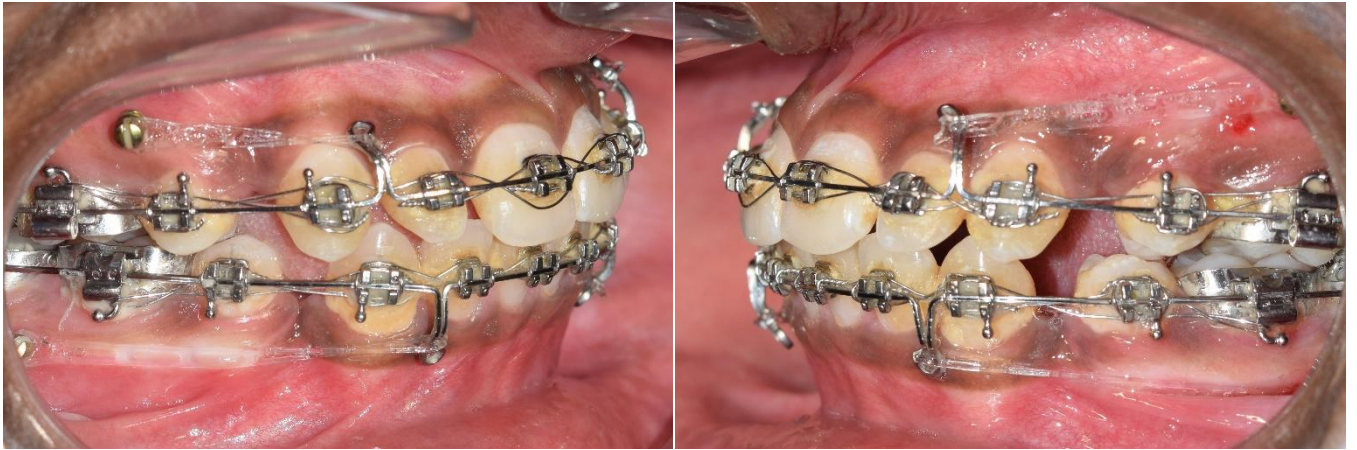
AGE/SEX: 18/M

MALOCCLUSION- : CLASS I

BIMAXILLARY PROTRUSION

OPD NO: 21225

All four 1st Premolar extraction followed by TAD assisted en-masse retraction



PATIENT 5

NAME: VENKATESH

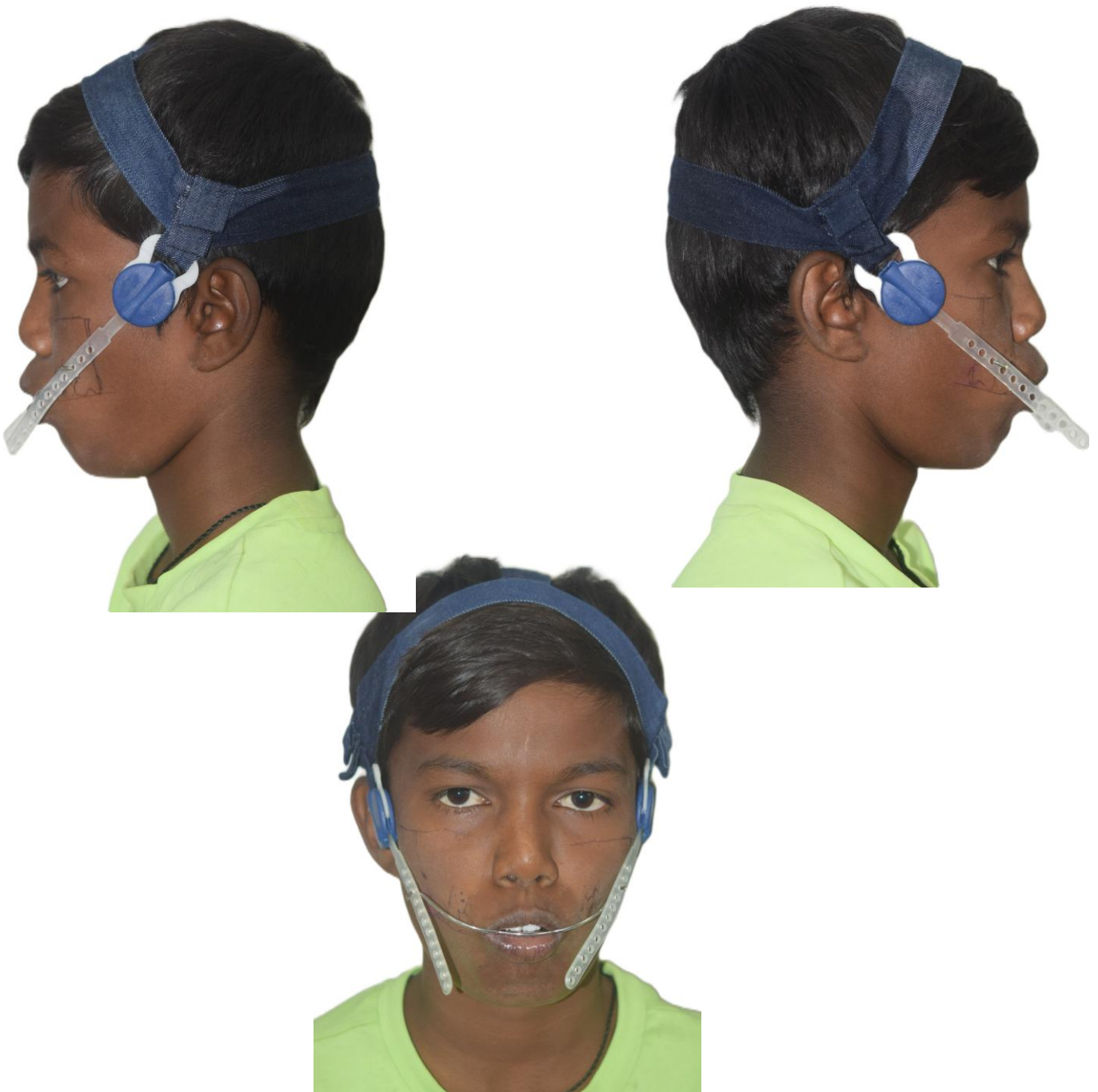AGE/SEX: 14/M

MALOCCLUSION ; CLASS II DIV I

MALOCCLUSION

MECHANICS; HIGH PULL HEADGEAR

OPD NO: 2140



PATIENT 6

NAME: SADIYA KHANUM

AGE/SEX: 23/F

MECHANICS; CANINE DISIMPACTION

OPD NO: 25947

