

AMES DENTAL COLLEGE AND HOSPITAL, RAICHUR

DEPARTMENT OF CONSERVATIVE DENTISTRY AND ENDODONTICS

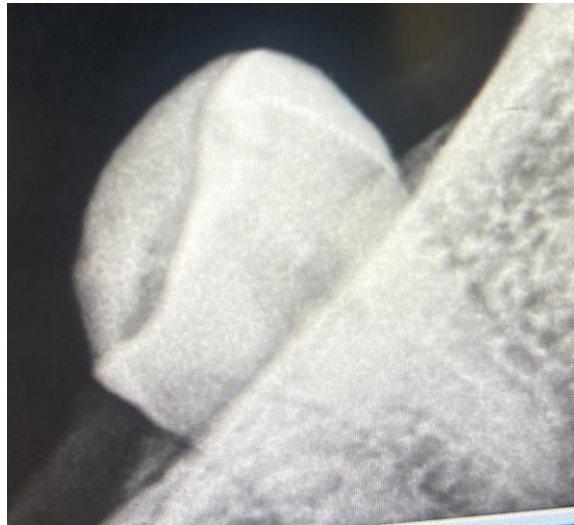CLASS I COMPOSITE RESTORATION

NAME OF THE PATIENT: Mr. Sanjay

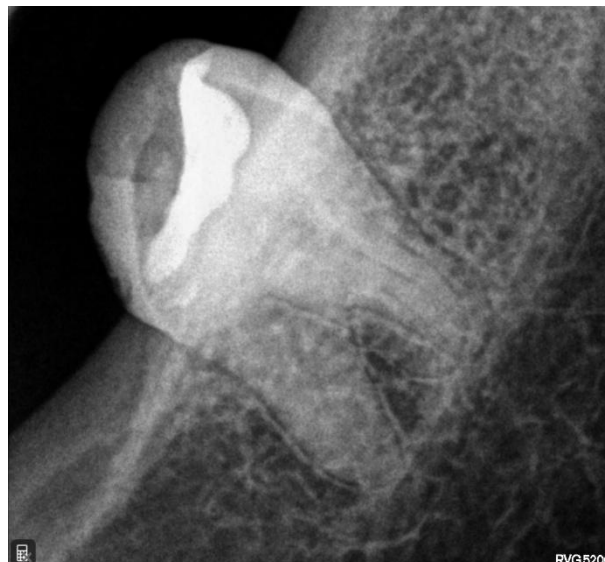OP NO: 12471

AGE AND SEX: 23Years / Male

PRE-OPERATIVE



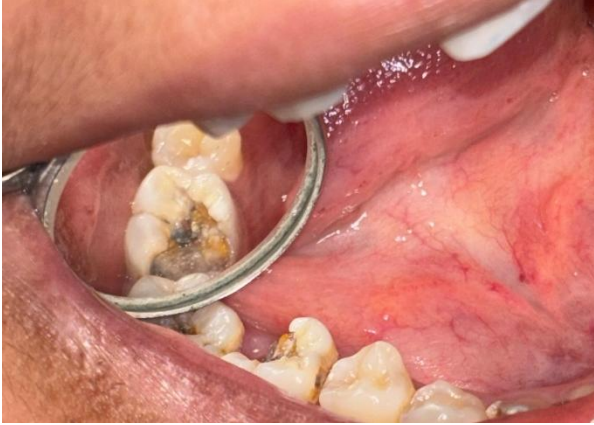POST-OPERATIVE



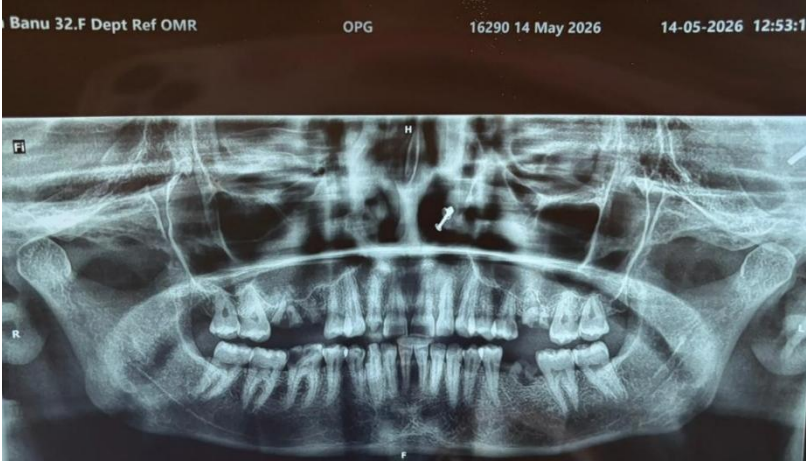OPERATED BY: DR. TEJAS RAJU GOULI [1ST YEAR PG]

DEPARTMENT OF CONSERVATIVE DENTISTRY AND ENDODONTICS

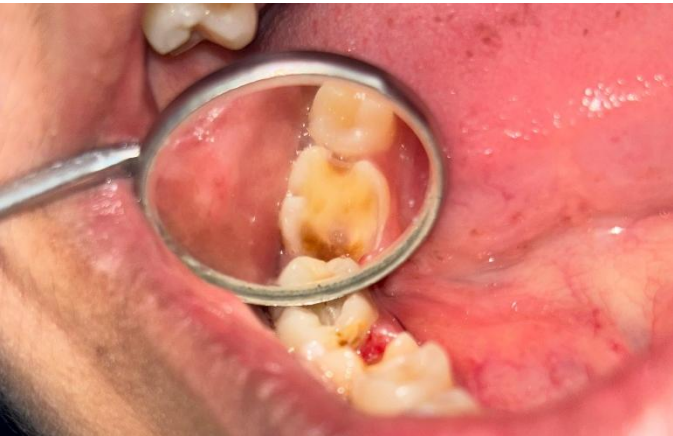DIRECT COMPOSITE ONLAY WITH 46



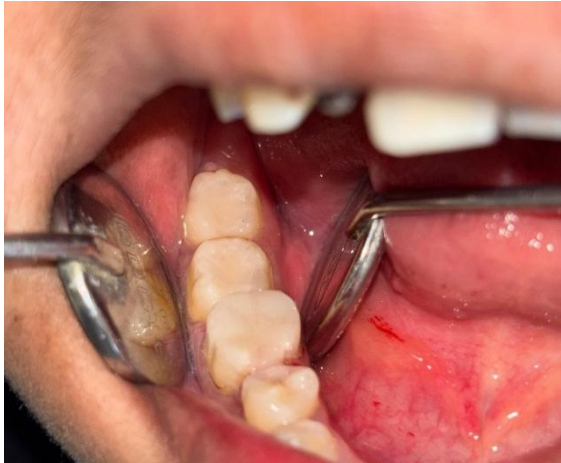PREOPERATIVE PHOTOGRAPH OF DEEP DISTO-OCCLUSAL CARIES WITH 46



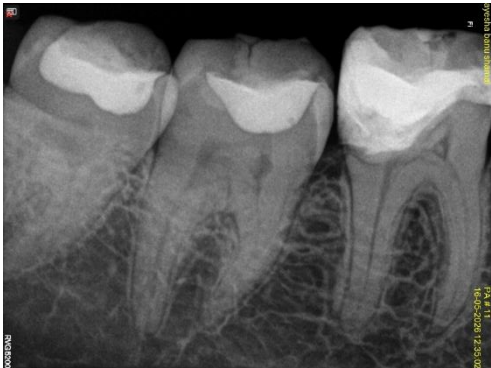PREOPERATIVE OPG



CARIES EXCAVATION DONE WITH 46, 47, 48

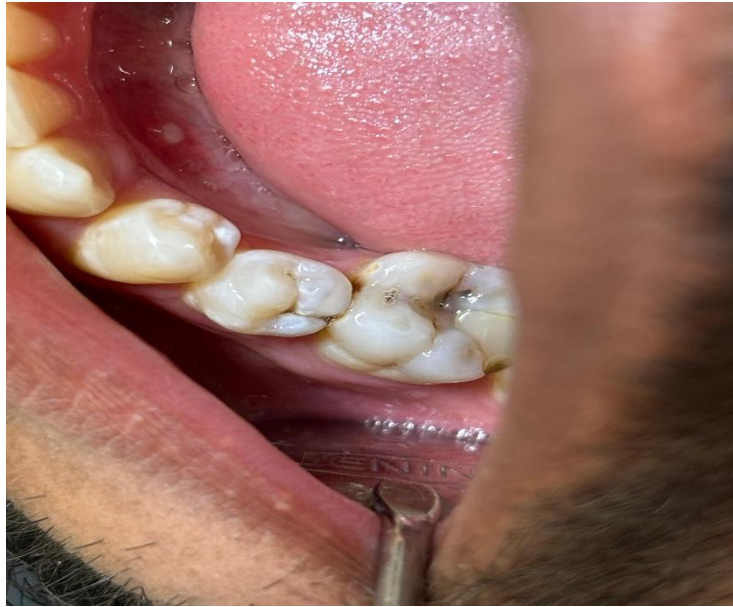

LIGHT CURE MTA PLACED WITH 46 AND DIRECT COMPOSITE ONLAY DONE WITH 46 AND COMPOSITE RESTORATION DONE WITH 47, 48

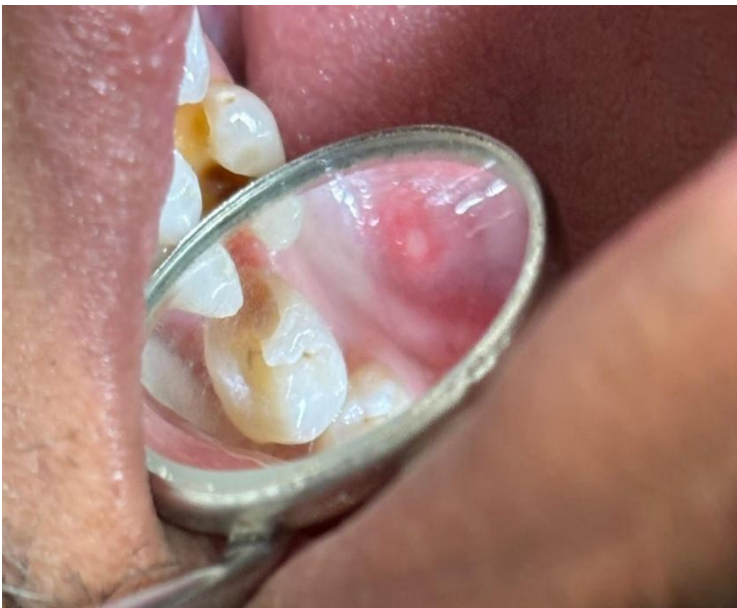

POSTOPERATIVE RADIOGRAPH WITH 46,47,48

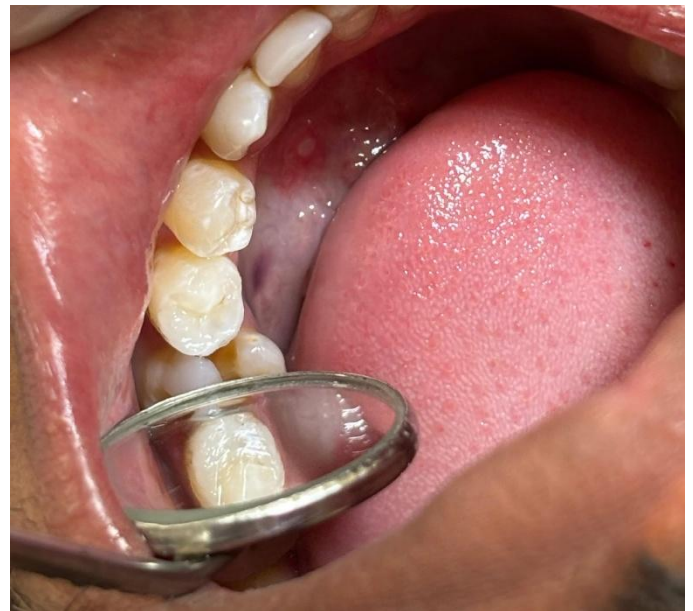DIRECT COMPOSITE FILLING IN ROTATED 35



PREOPERATIVE PHOTOGRAPH OF PROXIMAL
CARIES WITH ROTATED 35



CARIES EXCAVATION OF ROTATED 35



POSTOPERATIVE PHOTOGRAPH OF DIRECT
COMPOSITE FILLING OF ROTATED 35

AMES DENTAL COLLEGE AND HOSPITAL, RAICHUR

DEPARTMENT OF CONSERVATIVE DENTISTRY AND ENDODONTICS

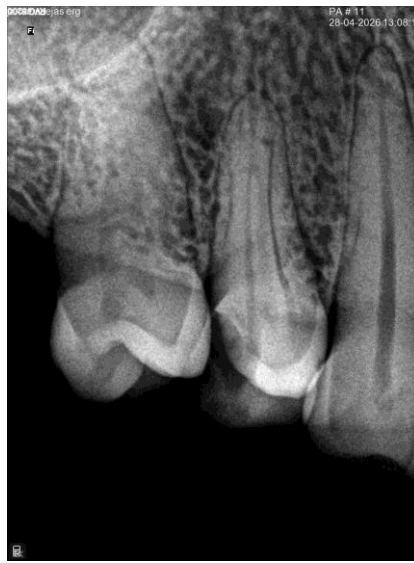DIRECT PULP CAPPING

NAME OF THE PATIENT: Mr. Sangeetha

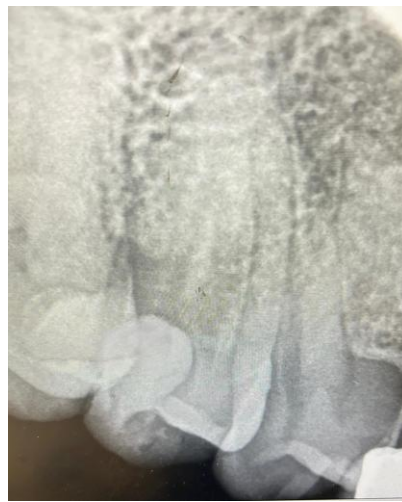OP NO: 50801

AGE AND SEX: 26 Years / Female

PRE-OPERATIVE



POST-OPERATIVE



OPERATED BY: DR. TEJAS RAJU GOULI [1ST YEAR PG]

AMES DENTAL COLLEGE AND HOSPITAL, RAICHUR

DEPARTMENT OF CONSERVATIVE DENTISTRY AND ENDODONTICS

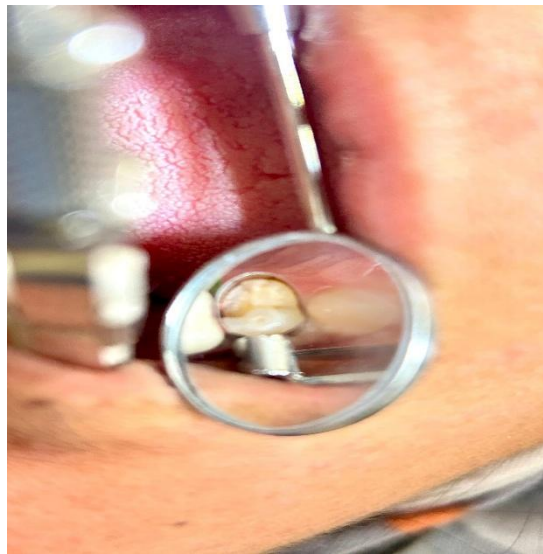DEEP MARGINAL ELEVATION

NAME OF THE PATIENT: Mrs. Jamuna

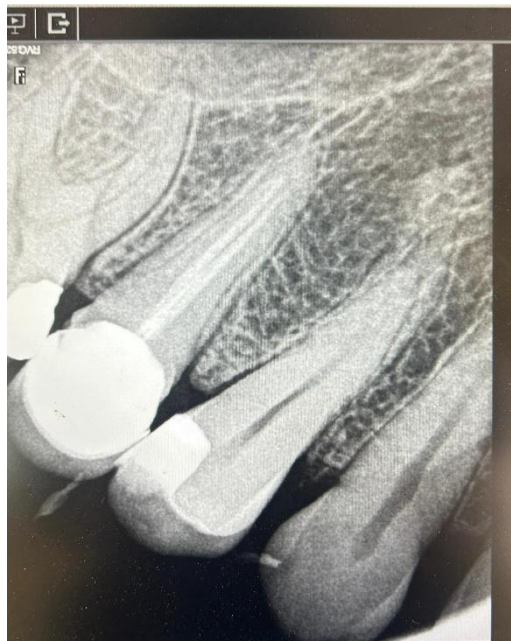OP NO: 4917

AGE AND SEX: 28 Years / Female

MATRIX BAND APPLICATION

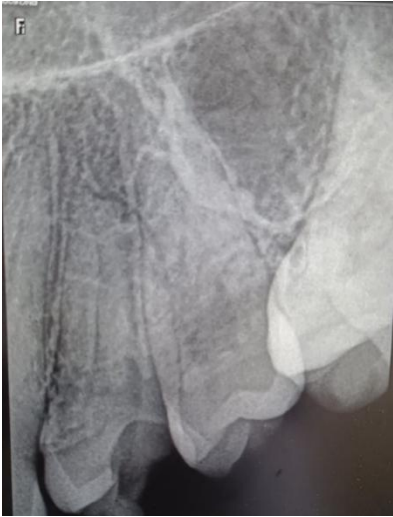

POST-OPERATIVE

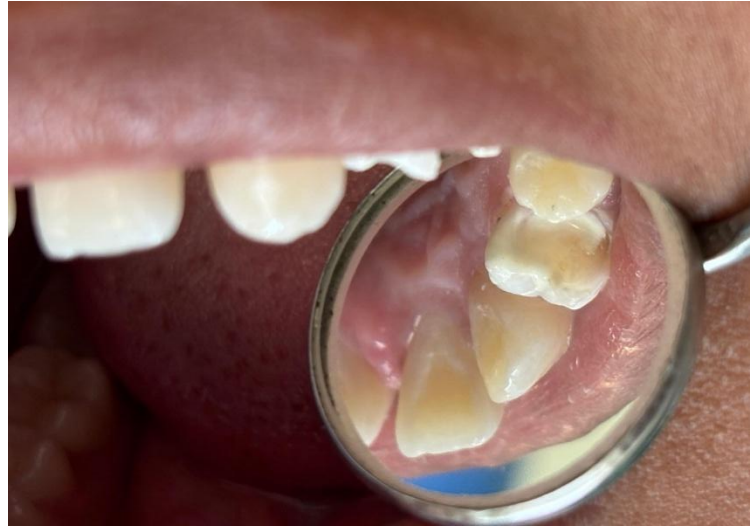

OPERATED BY: DR. TEJAS RAJU GOULI [1ST YEAR PG]

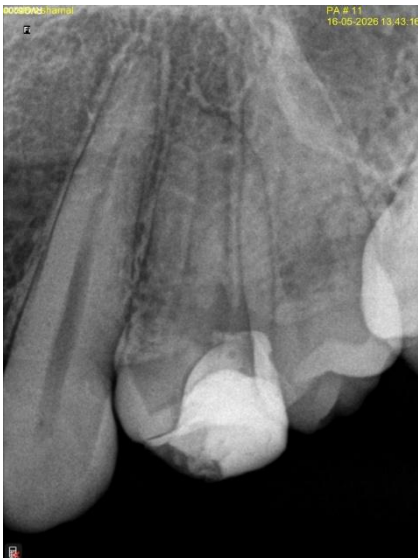FIBRE-REINFORCED COMPOSITE FILLING WITH 24



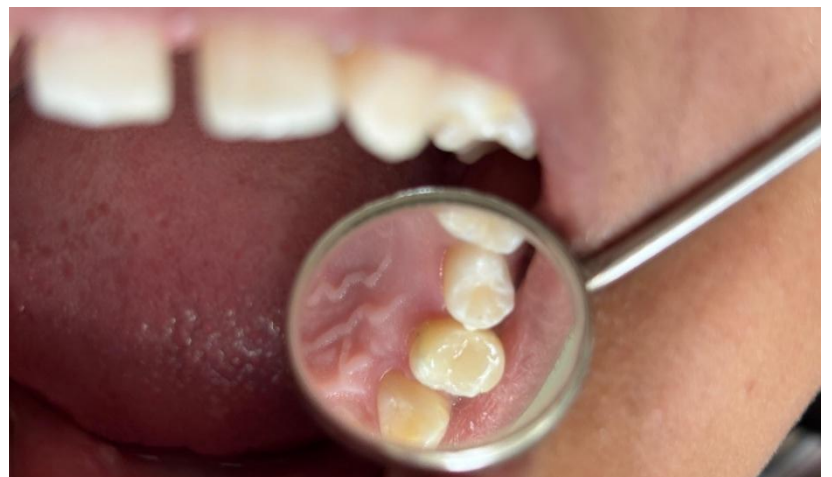DEEP DISTO-OCCLUSAL CARIES WITH 24 WITH ADJACENT ROTATED 25



CARIES EXCAVATION AND LIGHT CURE MTA PLACEMENT DONE WITH 24

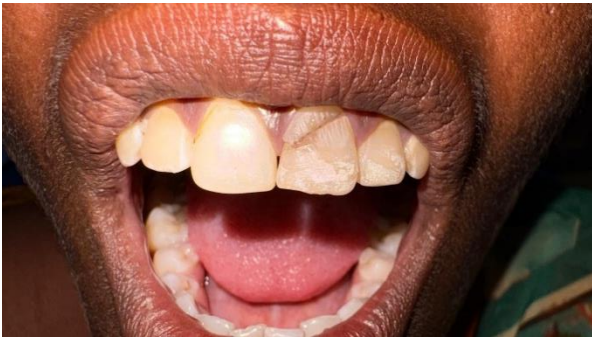

POSTOPERATIVE RADIOGRAPH

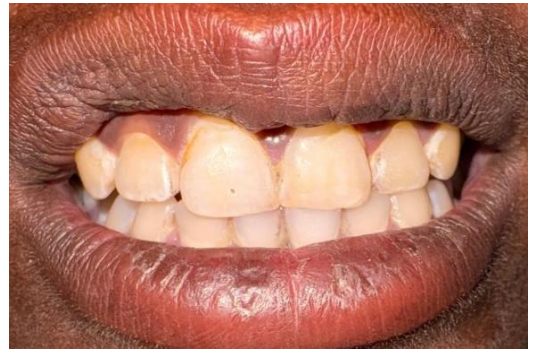


INTERLIG PLACED WITH 24 & DIRECT FILLING USING FLOWABLE AND PACKABLE COMPOSITE DONE WITH 24

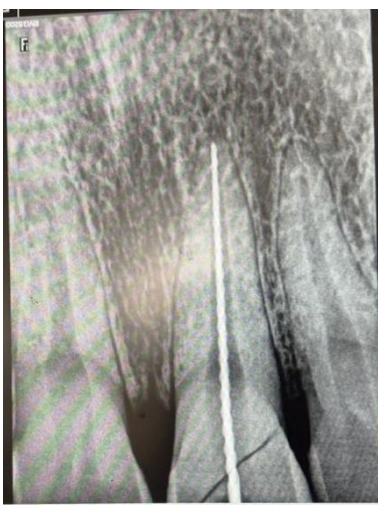DEPARTMENT OF CONSERVATIVE DENTISTRY & ENDODONTICS



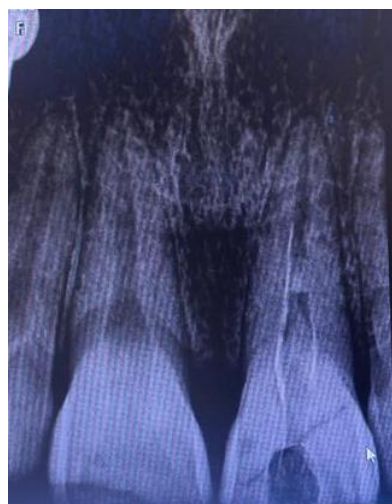Preoperative photograph of
Fractured upper left central incisor



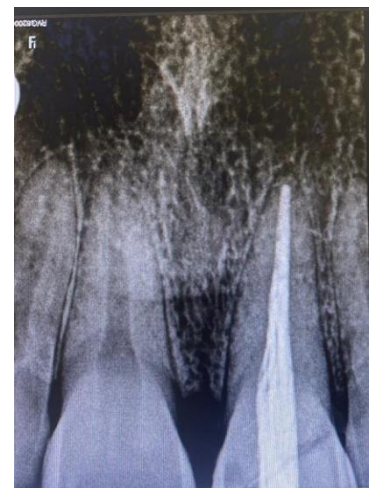Post operative photograph



Working length determination

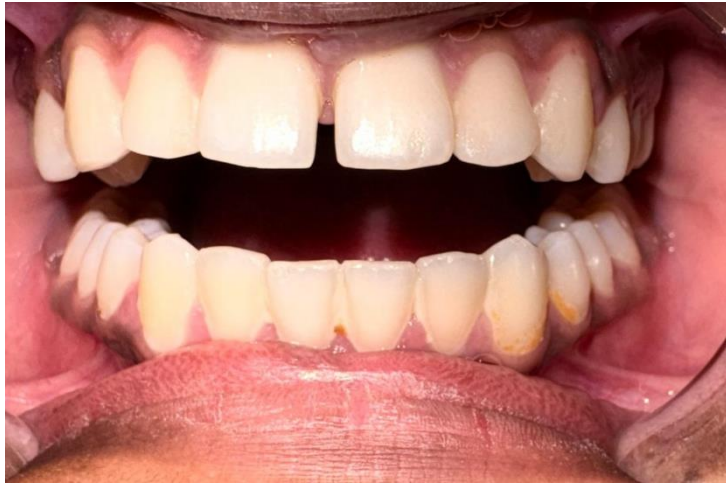

Intracanal medicament
placement

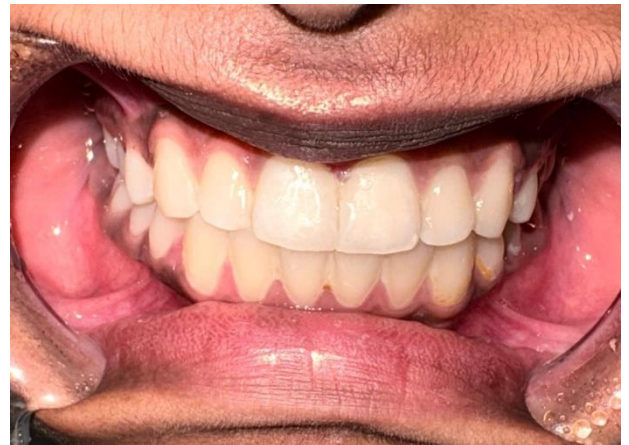
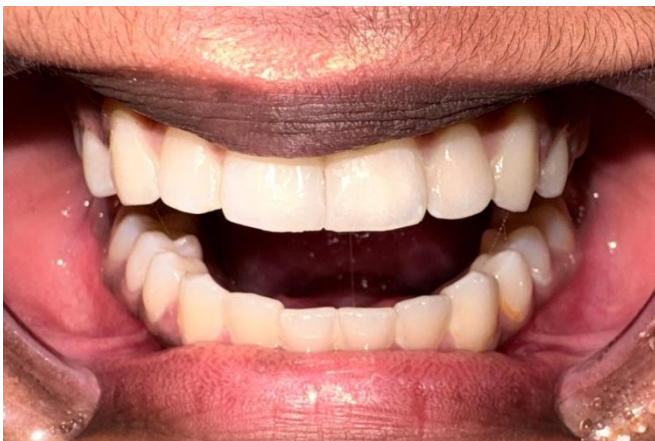
Obturation using lateral
condensation

DEPARTMENT OF CONSERVATIVE DENTISTRY & ENDODONTICS

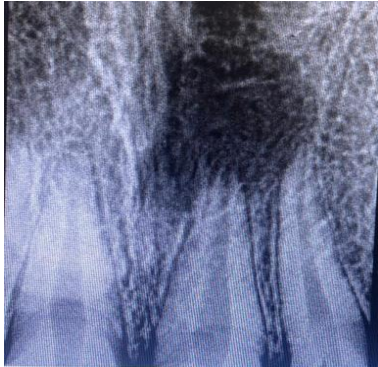

Preoperative photograph of midline diastema i.r.t 11,21

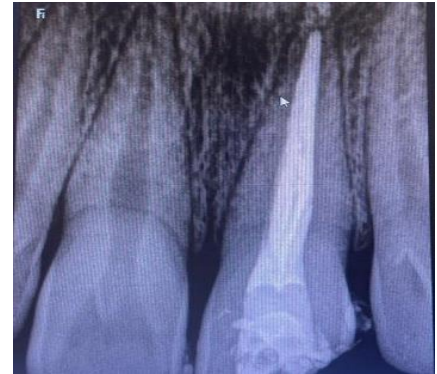

Post operative photograph of midline diastema closure i.r.t 11,21

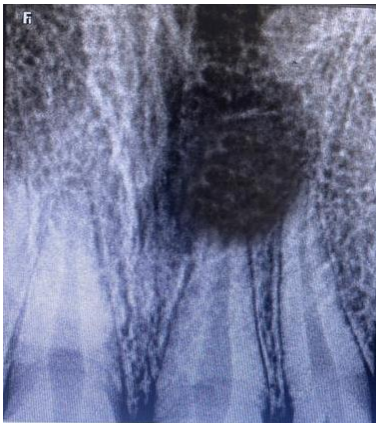DEPARTMENT OF CONSERVATIVE DENTISTRY & ENDODONTICS



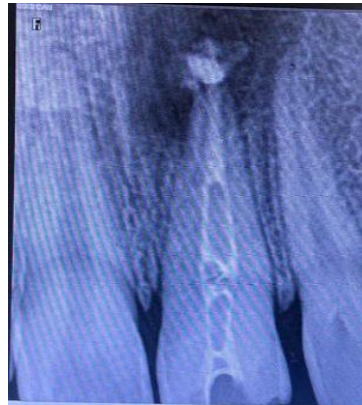Preoperative radiograph reveals open apex i.r.t 21



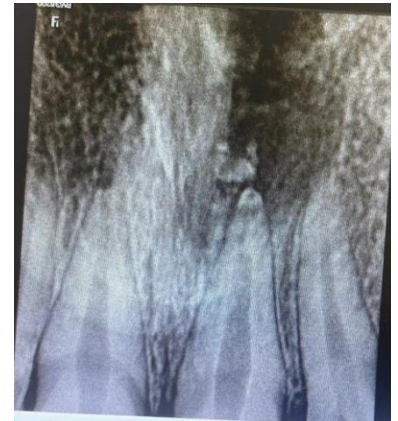Post operative radiograph reveals calcific bridge formation followed by obturation i.r.t 21



Initial Biomechanical preparation done till No.35 K file

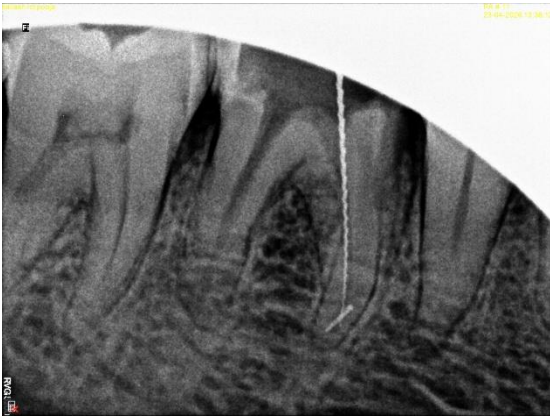


Calcium hydroxide Intracanal medicament placement i.r.t 21

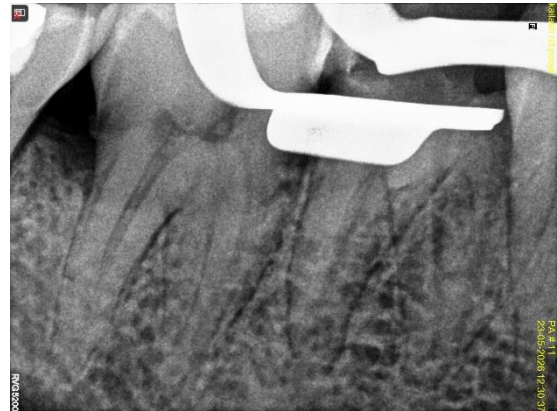

Calcific barrier formed i.r.t 21 after 7months follow up.

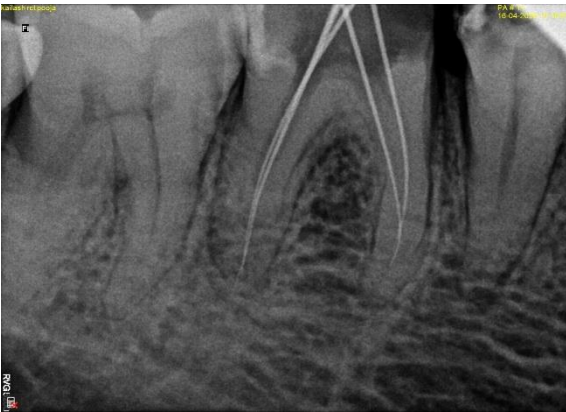
DEPARTMENT OF CONSERVATIVE DENTISTRY & ENDODONTICS



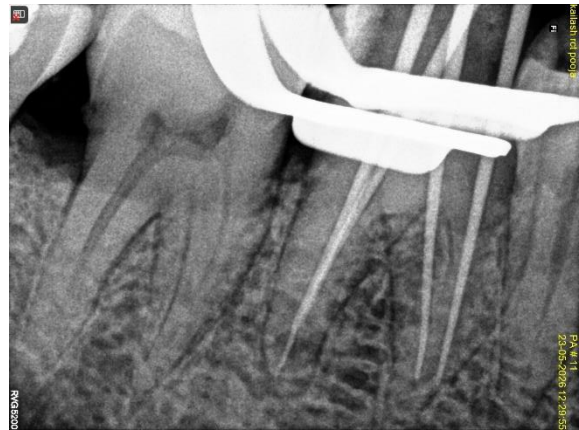File separation seen i.r.t 46



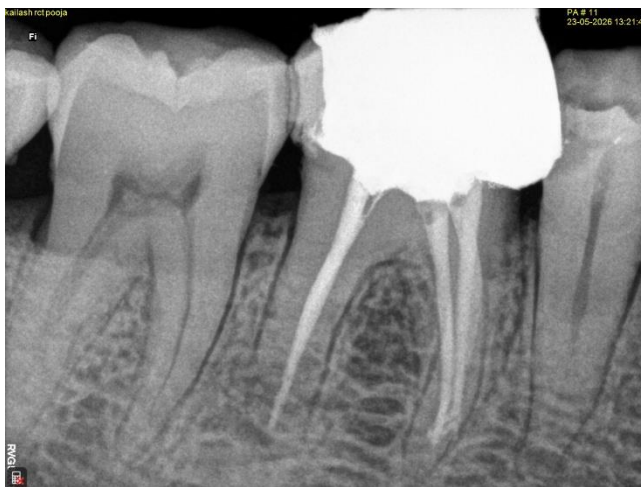File retrieval done i.r.t 46



Working length determination i.r.t 46



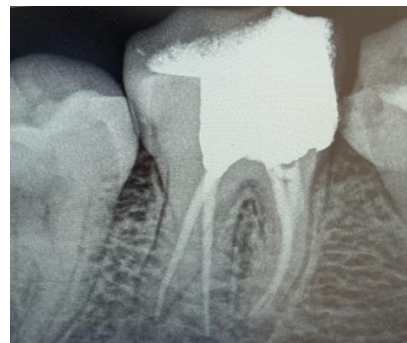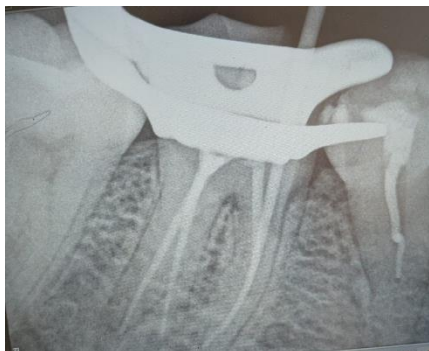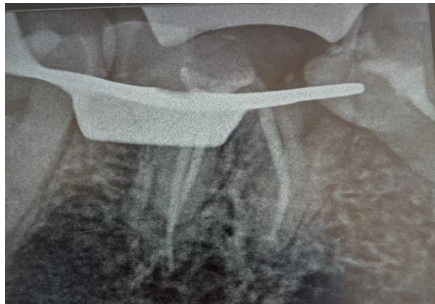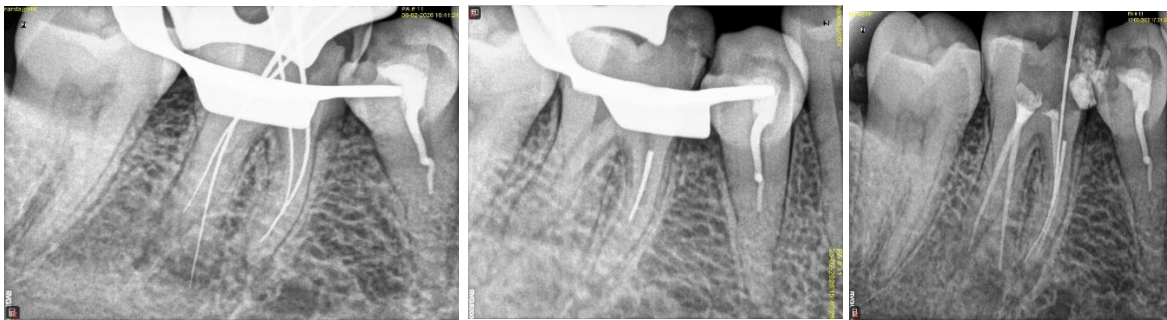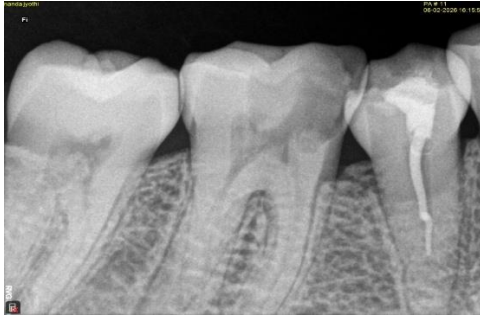Master cone selection i.r.t 46



Obturation done i.r.t 46

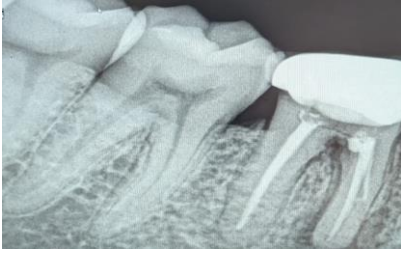Instrument separation followed by retrieval

Pre operative x-ray

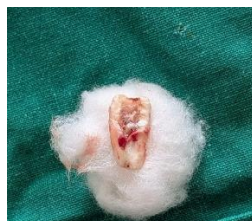
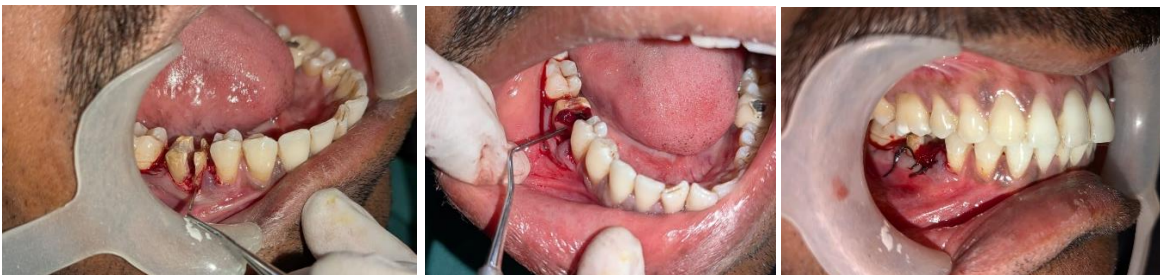
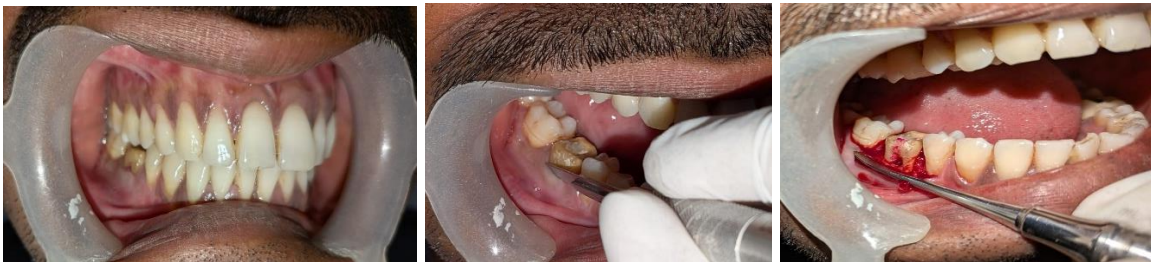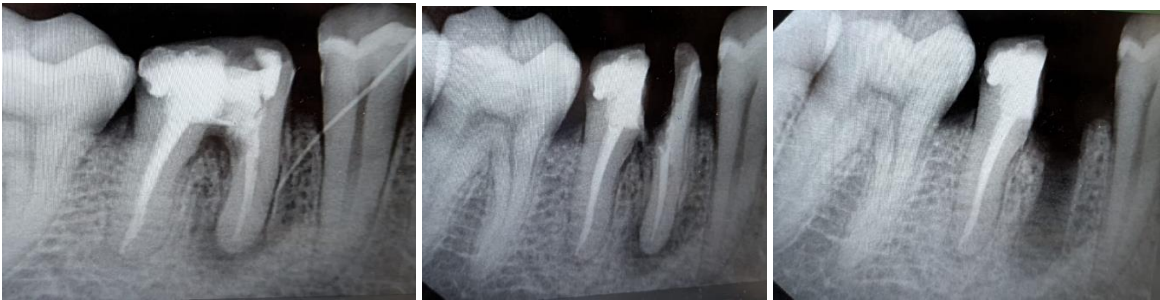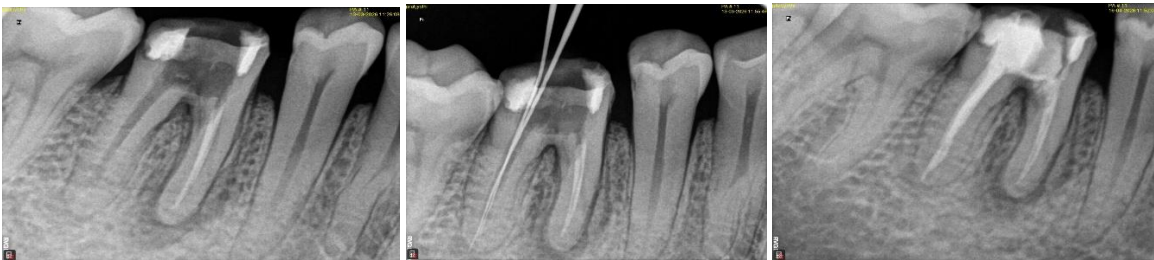Retreatment followed by Hemisection

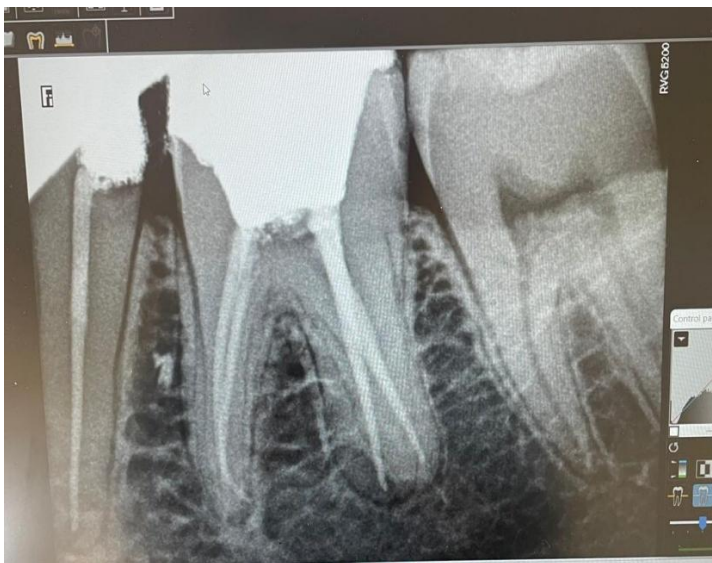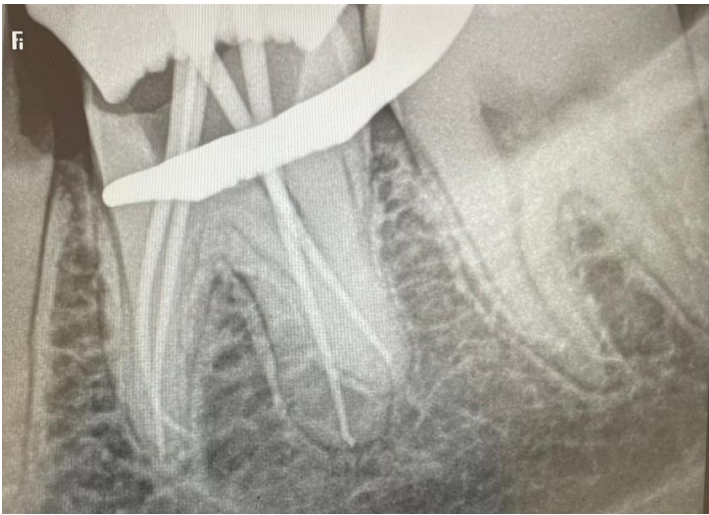
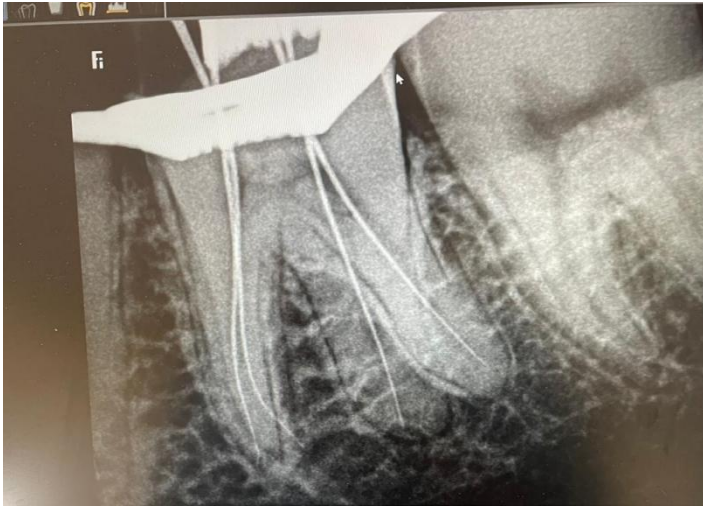
Pre operative



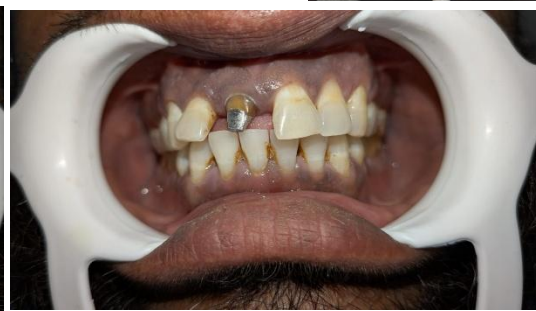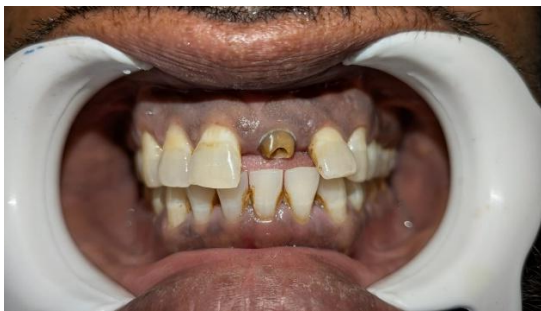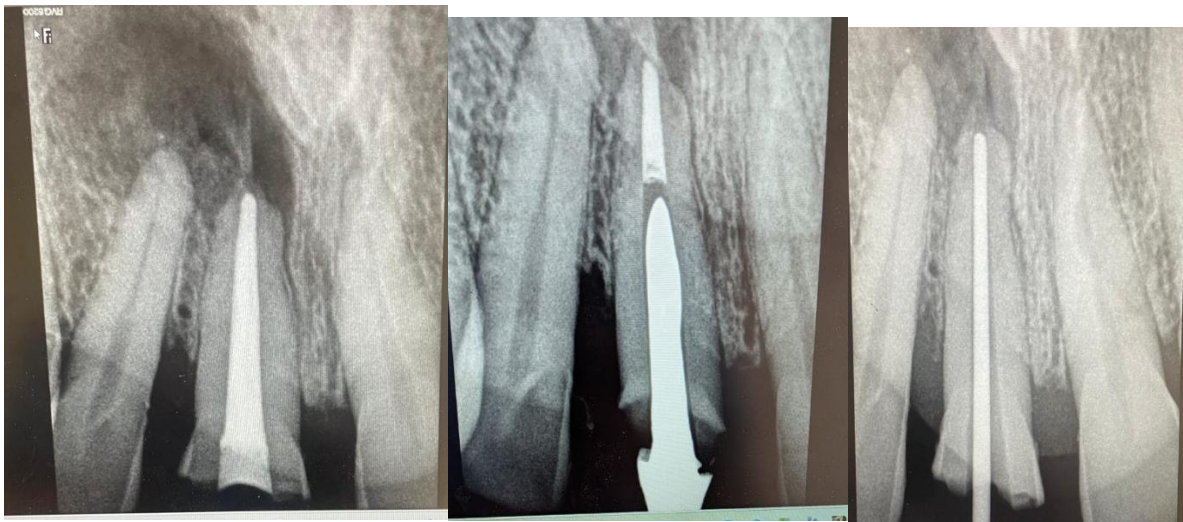
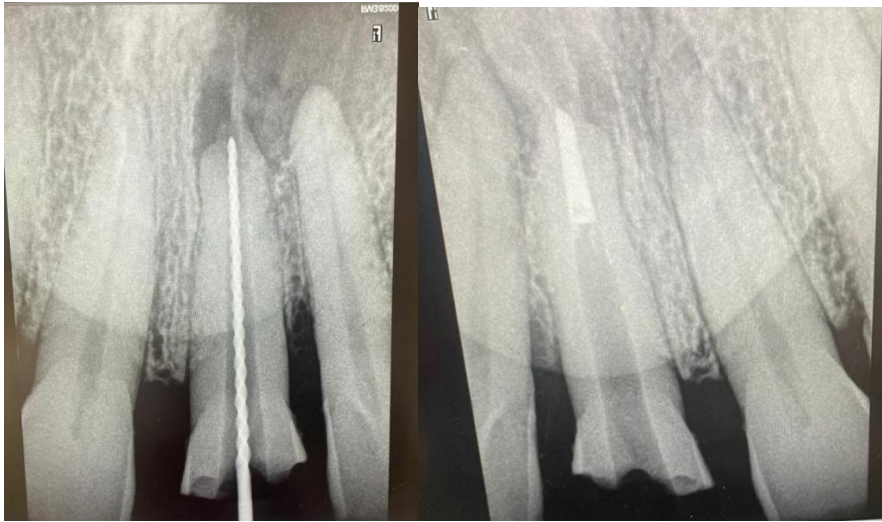
Hemisection of tooth



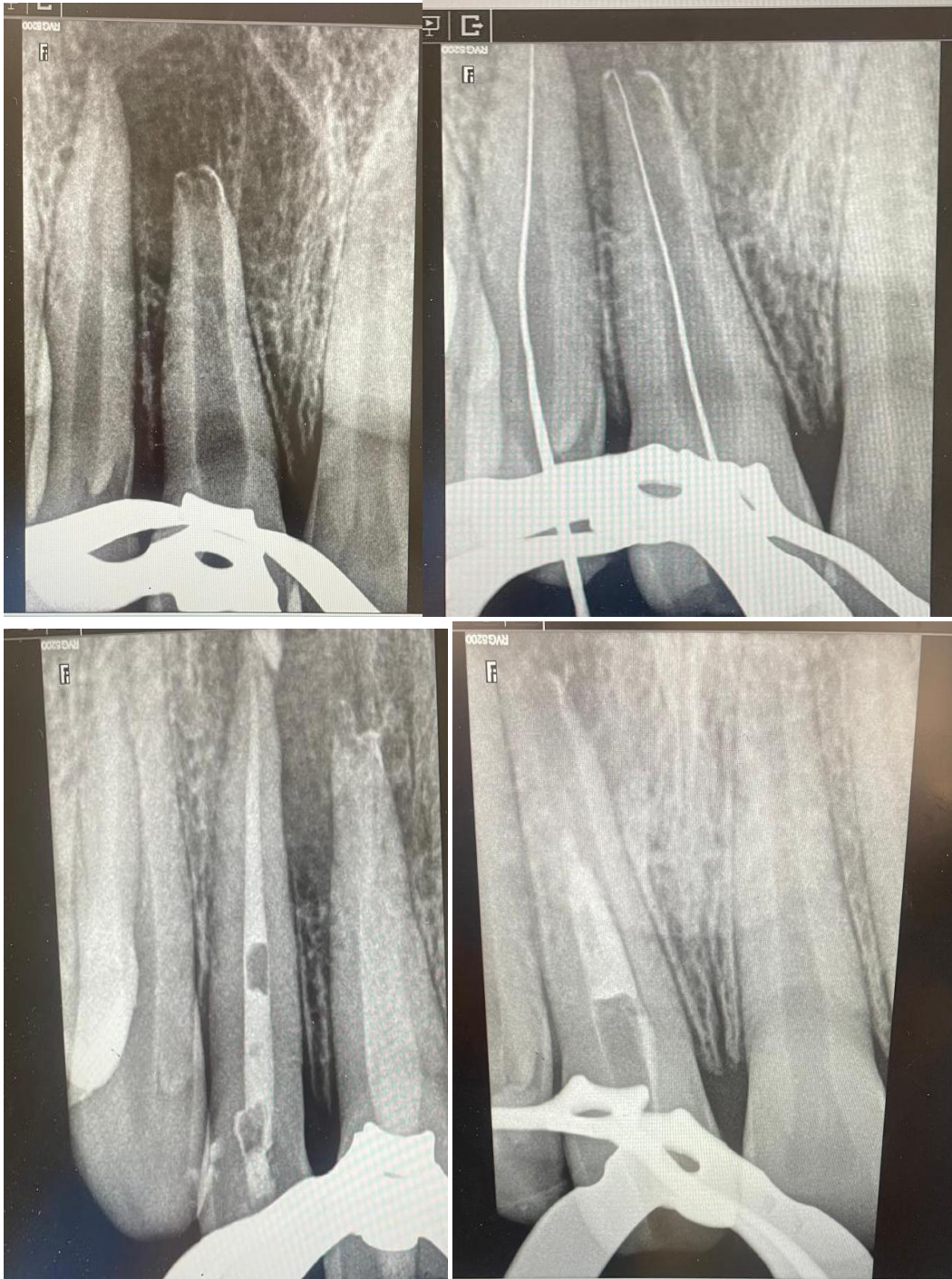PARAMOLARIS



POST AND CORE

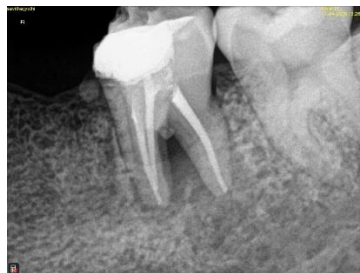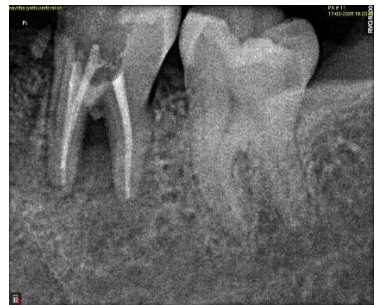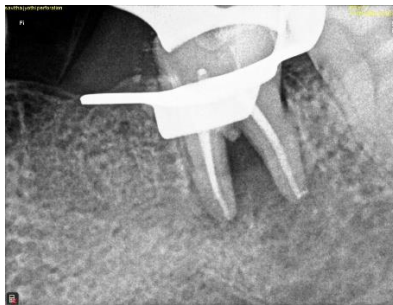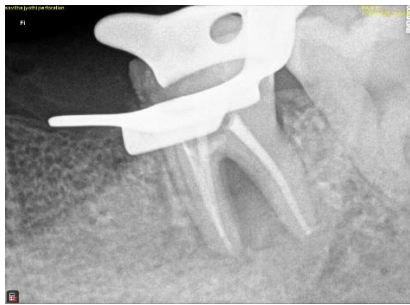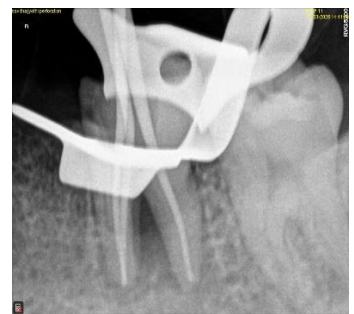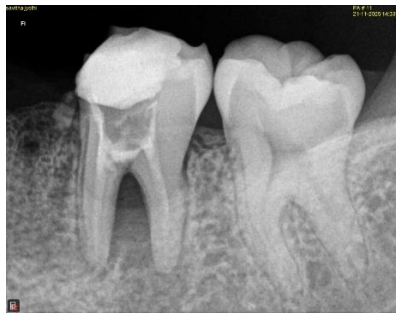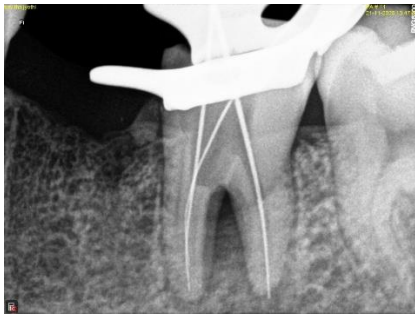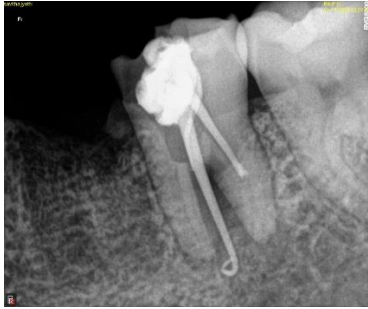


REGENERATIVE ENDODONTICS



Retreatment followed by perforation repair

Preoperative x ray



AMES DENTAL COLLEGE AND HOSPITAL, RAICHUR

DEPARTMENT OF CONSERVATIVE DENTISTRY AND ENDODONTICS

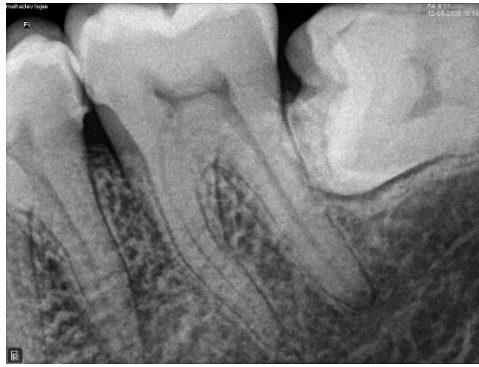CLASS I COMPOSITE RESTORATION

NAME OF THE PATIENT: Mr. Mahadeva

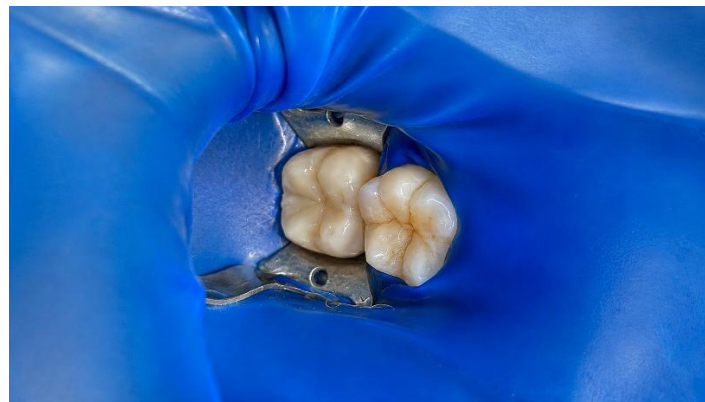OP NO: 14689

AGE AND SEX: 34 Years / Male

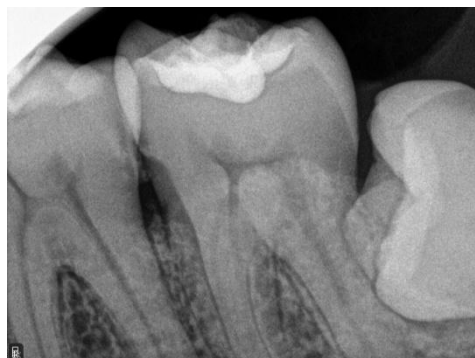PRE-OPERATIVE



RUBBER DAM ISOLATION



POST-OPERATIVE



OPERATED BY: DR. TEJAS RAJU GOULI [1ST YEAR PG]